Screening for Varices and Prevention of Bleeding

This is a PDF version of the following document:
Module 3: Management of Cirrhosis-Related Complications
Lesson 3: Screening for Varices and Prevention of Bleeding

You can always find the most up-to-date version of this document at https://www.hepatitisC.uw.edu/go/management-cirrhosis-related-complications/varices-screening-prevention-bleeding/core-concept/all.

Pathophysiology and Portal Dynamics

Pathogenesis of Portal Hypertension

In persons with cirrhosis, portal hypertension is characterized by an increase in intrahepatic vascular resistance and increased portal blood flow.[1,2,3] The increased resistance in the liver results from architectural distortion due to fibrosis and regenerative nodules combined with increased intrahepatic vasoconstriction due to decreased endogenous nitric oxide production and endothelial dysfunction. In the presence of angiogenic factors and increased nitrous oxide production in the splanchnic vascular bed, splanchnic arteriolar vasodilatation and increased cardiac output increase portal venous blood inflow.[3,4]

Portosystemic Collaterals

Collaterals develop in response to the portal hypertension at sites of communication between the portal and systemic circulations; these collaterals are accompanied by splanchnic vasodilatation.[2,3] In comparison to other collaterals, gastroesophageal varices are important due to their risk of rupture and bleeding.

Hepatic Venous Pressure Gradient

The hepatic venous pressure gradient is a measure of portal (sinusoidal) pressure and can be obtained by passing a balloon catheter under radiologic guidance into the hepatic vein via the jugular or femoral vein.[3,4] The free hepatic vein pressure is subtracted from the wedged hepatic vein pressure to calculate the hepatic venous pressure gradient, which normally is 3 to 5 mm Hg, and an elevated value indicates an intrahepatic cause of portal hypertension.[3,4] Due to the invasive nature of the procedure used to obtain the hepatic venous pressure gradient, it is not widely used in the United States for prognostic or therapeutic monitoring purposes.[3,5] The hepatic venous pressure gradient predicts the risk of developing varices and overall prognosis (Figure 1).[3,5] It can also be followed to monitor response to therapy and progression of liver disease. The following definitions summarize contemporary definitions for portal hypertension based on the hepatic venous pressure gradient.[1,2,4]

- **Portal Hypertension**: any hepatic venous pressure gradient greater than 5 mm Hg is considered as portal hypertension.
- **Mild Portal Hypertension**: defined as a hepatic venous pressure gradient greater than 5 mm Hg but less than 10 mm Hg.
- **Clinically Significant Portal Hypertension**: defined as hepatic venous pressure gradient value of 10 mm Hg or greater.

Diagnosing Clinically Significant Portal Hypertension and Predicting Varices

Due to its invasive nature, direct measurement of hepatic venous pressure gradient is not widely used in the United States to diagnose clinically significant portal hypertension. The 2023 AASLD Practice Guidance on Risk Stratification and Management of Portal Hypertension and Varices in Cirrhosis advises using noninvasive markers, including platelet counts and liver stiffness (determined by transient elastography), to determine the likelihood of clinically significant portal hypertension.[1] Clinically significant portal hypertension can be excluded if the platelet counts are greater than 150,000/mm^3 and liver stiffness is less than 15kPa. In contrast, clinically significant portal hypertension is highly probable if: (1) liver stiffness is 25 kPa or greater, (2) liver stiffness is 20-25 kPa and platelet counts are less than 150,000/mm^3, or (3) liver stiffness is 15-20 kPa and platelet counts are less than 100,000/mm^3.[1] In addition, persons with compensated cirrhosis who have liver stiffness measurements less than 20 kPa and platelet counts greater than 150,000/mm^3 (Baveno VI criteria) are at low risk (less than 5%) of having high-risk varices, and do not need screening endoscopy.[6] Further, the development of new portosystemic collaterals and progressive splenic enlargement on an imaging test is associated with the formation of varices.[6] Newer methods, such as magnetic resonance elastography and shear wave elastography, have been used to measure spleen and liver stiffness, but cutoffs for predicting clinically significant portal hypertension have not been well validated. Spleen stiffness measurements by transient elastography correlate well with hepatic venous pressure gradient but are not recommended for routine clinical use at this time.

Management of Compensated Cirrhosis with Clinically Significant Portal Hypertension

A major update in the 2023 AASLD Practice Guidance is to recommend nonselective beta-blocker therapy in patients with cirrhosis and clinically significant portal hypertension to decrease the risk of decompensation.[1] This recommendation was based on results of a randomized controlled trial and systematic review meta-analysis, which showed that patients with compensated cirrhosis and clinically significant portal hypertension given nonselective beta-blockers had significantly lower risk of decompensation compared to those not on nonselective beta-blockers.[7,8] The 2023 AASLD Practice Guidance also recommended carvedilol (12.5 mg/day) as the preferred nonselective beta-blocker of choice.[1] Patients with clinically significant portal hypertension and contraindications to nonselective beta-blockers should undergo screening esophagogastroduodenoscopy (EGD) to evaluate for the presence of gastroesophageal varices. Similarly, if transient elastography or imaging surrogates of clinically significant portal hypertension are not available and empiric use of nonselective beta-blocker is contraindicated, patients with compensated cirrhosis should undergo EGD. However, screening EGD is not necessary in patients taking a nonselective beta-blocker. Notably, nonselective beta-blockers are not recommended to prevent decompensation in patients with compensated cirrhosis without clinically significant portal hypertension. These patients should undergo annual transient elastography to assess for clinically significant portal hypertension and/or Baveno VI endoscopic criteria. An upper endoscopy should also be performed at the onset of a decompensating event in persons with small or no known esophageal varices to assess for progression of portal hypertension and should be repeated annually.

Management with No Varices Found on EGD

For patients with compensated cirrhosis and clinically significant portal hypertension who are not taking a nonselective beta-blocker, if no varices are found on EGD (Figure 2), a follow-up EGD should be performed in 2 to 3 years.[6,9] The 2-year interval is recommended in persons who have ongoing liver injury or associated comorbidities, such as obesity or alcohol use; the 3-year interval is considered appropriate when the liver injury is considered quiescent, such as following viral elimination or abstinence from alcohol.[1] An upper endoscopy should also be performed at the onset of a decompensating event in persons with no known esophageal varices to assess for progression of portal hypertension and should be repeated annually.

Management with Varies Found on EGD

If esophageal varices are found (Figure 3), they should be classified into one of two grades: small (less than or equal to 5 mm) or medium/large (greater than 5 mm). Annual follow-up endoscopy is recommended for persons with small varices and ongoing liver injury; those with small varices and no ongoing liver injury should have follow-up endoscopy every 2 years.[1] In addition, for persons with small esophageal varices, an upper endoscopy should be performed at the onset of a decompensating event to assess for progression of portal hypertension and should be repeated annually thereafter. The size of the varices found on endoscopy impacts the management and prophylaxis against variceal hemorrhage, as discussed below.

Prophylaxis of Variceal Bleeding

Persons with compensated cirrhosis will typically develop varices at a rate of 7 to 8% per year.[10] In addition, individuals with small esophageal varices have progression to large varices at a rate of 10 to 12% per year.[11] It is important to decrease the risk of variceal hemorrhage, which occurs at a rate of approximately 10 to 15% per year; the highest rates of hemorrhage occur in persons with large varices, decompensated cirrhosis, or red wale markings on the varices.[12,13] The following summarizes the terminology used to describe prophylaxis of variceal bleeding.

- **Primary Prophylaxis**: the prevention of variceal hemorrhage in persons with known esophageal varices but no history of variceal hemorrhage.
- **Secondary Prophylaxis**: variceal hemorrhage prevention measures for persons with a known history of variceal hemorrhage.

Primary Prophylaxis

The approach to primary prophylaxis depends on the findings from the screening EGD (Figure 4).[1] If no varices are observed at the time of EGD, then primary prophylaxis is not indicated. As noted above, these persons without varices should have follow-up EGD in 2 to 3 years if they have compensated cirrhosis and annually if they have decompensated cirrhosis.[1]

Small Esophageal Varices

Experts have usually defined small esophageal varices as 5 mm or less, straight (nontortuous), and minimally elevated above the esophageal mucosal surface (Figure 5).[4,14,15] For patients not receiving prophylaxis with a nonselective beta-blocker, EGD should be repeated (1) annually if there is ongoing liver injury or hepatic decompensation, (2) every 2 years for those individuals with liver injury that is quiescent, or (3) at the time of hepatic decompensation. Persons taking a nonselective beta-blocker do not need a follow-up EGD in the absence of a prior history of variceal hemorrhage.

Medium and Large Esophageal Varices

The 2023 AASLD Practice Guidance on Risk Stratification and Management of Portal Hypertension and Varices in Cirrhosis classifies AASLD practice guidance on Portal Hypertensive Bleeding in Cirrhosis classifies medium and large varices in the same category for variceal bleeding prophylaxis recommendations.[1] The medium/large category of varices consists of varices greater than 5 mm in size that typically have a more prominent and tortuous appearance within the esophageal lumen than seen with small varices (Figure 6). For individuals with medium/large varices, use of a nonselective beta-blocker or treatment with endoscopic variceal ligation has been shown to significantly reduce the risk of variceal bleeding.[12,16,17,18] In a meta-analysis, endoscopic variceal ligation reduced the risk of bleeding slightly more than nonselective beta-blocker use, but there was no difference in mortality, and endoscopic variceal ligation is associated with a risk of procedure-related complications.[16] One randomized controlled trial examined the combined use of nonselective beta-blockers and endoscopic variceal ligation versus endoscopic variceal ligation alone and found the combined therapy had no benefit but was associated with increased adverse effects.[19] For persons with medium/large varices, the 2023 AASLD guidance recommends primary prophylaxis with either (1) a nonselective beta-blocker (including carvedilol) or (2) endoscopic variceal ligation, with preference given to nonselective beta-blockers due to benefits beyond preventing variceal bleeding.[6]

Gastric Varices

The data for primary prophylaxis for typical cardiofundal varices or isolated fundic varices is more limited, but the 2023 AASLD guidance recommends using the same nonselective beta-blocker dosing goals used for esophageal varices.[1] In patients with a contraindication to nonselective beta-blockers and high-risk

cardiofundal varices, endoscopic cyanoacrylate injection may be considered to prevent initial hemorrhage. There are insufficient data to support transjugular intrahepatic portosystemic shunt (TIPS) or balloon-occluded retrograde transvenous obliteration to prevent initial variceal hemorrhage.

Nonselective Beta-Blockers

The nonselective beta-blockers decrease cardiac output (beta-1 effect) and induce splanchnic vasoconstriction (beta-2 effect), which decreases venous portal blood inflow. Experts recommend initiating at a low dose and increasing every 2 to 3 days, aiming for a resting heart rate of approximately 55 to 60 beats per minute while maintaining a systolic blood pressure of at least 90 mm Hg (and not exceeding the recommended maximal daily dose) (Figure 7).[6] Carvedilol is the preferred nonselective beta-blocker in the 2023 AASLD Practice Guidance because of its greater efficacy, better tolerability, and simpler administration, but in patients with low systolic blood pressure, propranolol or nadolol may be considered due to less antihypertensive effect.[1] Individuals receiving variceal prophylaxis need to continue the nonselective beta-blocker or carvedilol indefinitely, but they do not need follow-up EGD. Persons with decompensated cirrhosis should be monitored closely for side effects of the beta-blocker. If the individual receiving the beta-blocker develops persistently low systolic blood pressure (i.e. less than 90 mmHg) or spontaneous bacterial peritonitis, then the beta-blocker should be held.

Endoscopic Variceal Ligation

For individuals who undergo endoscopic variceal ligation as primary prophylaxis for variceal bleeding, the procedure should be repeated every 2 to 4 weeks until the varices are eradicated.[1] Following eradication of the varices, EGD should be performed 6 months later and then every 12 months thereafter.[1]

Treatment of Acute Variceal Bleeding

Variceal bleeding accounts for at least 70% of cases of upper gastrointestinal bleeding in persons with portal hypertension.[20,21,22] The mortality associated with an index variceal bleed is approximately 20%.[23,24] Initial treatment of bleeding is effective in 80 to 90% of individuals, but 25 to 35% have rebleeding in the subsequent 6 weeks, with approximately 50% of these episodes occurring within 5 to 10 days.[25,26,27] A hepatic venous pressure gradient greater than 20 mm Hg (measured within 24 hours of hospital admission) and Child-Turcotte-Pugh class C cirrhosis are strong predictors for failure to control bleeding, risk of early rebleeding, and death.[4,23,28] Mortality associated with acute variceal bleeding is approximately 15 to 20%, with most deaths due to liver failure, hepatorenal syndrome, and infections.[23,25] The management of variceal bleeding requires a multipronged approach, as indicated in the following recommendations based on the 2023 AASLD practice guidance on Portal Hypertensive Bleeding in Cirrhosis.[1]

General Management

The major goals in the management of persons with acute variceal bleeding are: (1) control bleeding, (2) prevent early rebleeding (within 5 days), and (3) reduce 6-week mortality.[6] Individuals with suspected variceal hemorrhage should be admitted to the intensive care unit and immediate efforts should be made to establish intravenous access and provide volume resuscitation to achieve hemodynamic stability.[6]

Transfusions of Packed Red Blood Cells

Transfusion of packed red blood cells should be restricted to a hemoglobin level of approximately 7 g/dL or lower, unless comorbid conditions such as ischemic coronary disease necessitate higher goals, since excessive transfusion increases portal pressure, risk of rebleeding, and short-term mortality.[6,29] For persons requiring red blood cell transfusions, the goal is to maintain a hemoglobin level between 7 and 9 g/dL.[6]

Correction of Coagulopathy

There is no evidence that fresh frozen plasma or platelet transfusions improve outcomes, and therefore, they should not be administered based on international normalized ratio (INR) or platelet targets.[6,30,31,32]

Vasoactive Agents

Use of vasoactive agents in persons with acute variceal bleeding clearly lowers transfusion requirements and improves 7-day mortality.[6,33] The vasoactive agents are splanchnic vasoconstrictors and include intravenous vasoconstrictors and somatostatin analogs.[34] A vasoactive agent should be started immediately in a patient with suspected variceal bleeding and octreotide, somatostatin, and terlipressin have similar efficacy, but different side effect profiles.[35,36] Although vasoactive medications decrease portal blood flow and therefore portal pressure, the effect is short-lived. Therefore, octreotide is most effective when used in combination with endoscopic therapy.[12,37] Vasoactive agents should be given for 2 to 5 days, unless a TIPS is placed.[1,6,36]

Table 1.

Vasoactive Agents for Acute Variceal Bleeding

Agent	Dosing	Duration
Octreotide	Initial i.v. bolus of 50 mcg and continue infusion at a rate of 25-50 mcg/hour	2-5 days
Somatastatin	Initial i.v. bolus of 250 mcg and continue	2-5 days

Agent	Dosing	Duration
	infusion at a rate of 250-500 mcg/hour	
Terlipressin*	Initial 24-48 hours: 2 mg i.v. every 4-6 hours and then 1 mg i.v. every 4-6 hours	2-5 days
*Not approved for this indication in North America		

Source:

- Garcia-Tsao G, Abraldes JG, Berzigotti A, Bosch J. Portal hypertensive bleeding in cirrhosis: Risk stratification, diagnosis, and management: 2016 practice guidance by the American Association for the study of liver diseases. Hepatology. 2017;65:310-335. [PubMed Abstract]
- Kaplan DE, Bosch J, Ripoll C, et al. AASLD practice guidance on risk stratification and management of portal hypertension and varices in cirrhosis. Hepatology. 2023 Oct 23. Online ahead of print. [PubMed Abstract]
- Seo YS, Park SY, Kim MY, et al. Lack of difference among terlipressin, somatostatin, and octreotide in the control of acute gastroesophageal variceal hemorrhage. Hepatology. 2014;60:954-63. [PubMed Abstract]

Infection Prophylaxis

For persons with gastrointestinal bleeding, including those with variceal bleeding, the use of a 7-day course of prophylactic antibiotics has been shown to reduce near-term mortality and decrease the rate of bacterial infection and risk of early rebleeding.[38] The preferred initial treatment consists of ceftriaxone 1 g daily.[3,39] The 2012 AASLD Guidance for Management of Ascites Due to Cirrhosis recommends initiating therapy in this situation with intravenous ceftriaxone, with the option to switch to oral therapy (norfloxacin) once bleeding stops and the patient has resumed oral intake.[40] Since norfloxacin is no longer available in the United States, most experts substitute oral ciprofloxacin 500 mg twice daily for norfloxacin in this situation. If intravenous ceftriaxone cannot be used due to a severe beta-lactam allergy, intravenous ciprofloxacin 400 mg every 12 hours can be used as the initial intravenous prophylaxis regimen during active bleeding.

Nonselective Beta-Blockers

Nonselective beta-blockers should not be started immediately in persons with acute variceal bleeding. If the patient is taking a nonselective beta-blocker, it should be held during the first several days of bleeding, especially if the patient is hemodynamically unstable. If a patient receives a 2- to 5-day course of intravenous octreotide, the nonselective beta-blocker can be started (or restarted) after completion of the octreotide course.[6] If the patient has a TIPS procedure performed, a nonselective beta-blocker is no longer needed.

Endoscopic Therapy

Esophagogastroduodenoscopy should be performed within 12 hours of admission, with immediate endoscopic variceal ligation of confirmed or suspected varices.[6] This procedure involves placing a small elastic band around the varices. Endoscopic sclerotherapy, which consists of injecting a sclerosant solution into the varices, has also been shown to be effective in stopping acute variceal bleeding, but is not recommended as an initial endoscopic therapeutic option, primarily because of better outcomes with endoscopic variceal ligation.[41,42]

Transjugular Intrahepatic Portosystemic Shunt

Several studies have shown placement of transjugular intrahepatic portosystemic shunt within 72 hours of endoscopic variceal ligation in high-risk persons results in lower risk of rebleeding and improved survival, but these individuals in the studies were highly selected and, in one study, constituted less than 20% of those admitted with variceal hemorrhage.[3,43,44] Individuals with Child-Turcotte-Pugh class C with a score of 10 to 13, or Child-Turcotte-Pugh class B with active bleeding visualized on endoscopy despite intravenous vasoactive drug therapy, should be recommended for TIPS within 72 hours (ideally within 24 hours of EGD), unless there are absolute contraindications to TIPS placement.[1] For persons with uncontrolled variceal hemorrhage despite intravenous vasoactive drugs and endoscopic therapy, rescue TIPS should also be considered.

Balloon Tamponade

Use of standard measures fails to control bleeding in approximately 10 to 20% of persons with variceal bleeding. In this setting, use of balloon tamponade may be necessary as a temporary stabilizing therapy until a more definitive procedure, such as endoscopic variceal ligation or TIPS, can be performed.[6,45] The use of balloon tamponade is associated with serious potential adverse effects, and it should not be used for longer than 24 hours.[6] Self-expandable metal esophageal stents were shown in a small multicenter, randomized, controlled trial to be a reasonable alternative to achieve hemostasis in those who did not respond to medical and endoscopic therapy, and these can remain in place up to seven days while awaiting more definitive therapy.[46]

Gastric Varices

Gastric varices are present in 20% of individuals with portal hypertension, but episodes of bleeding tend to be even more severe than esophageal variceal bleeding.[3,6,47] Acute fundal gastric variceal bleeding (1 to 3% of all variceal bleeding episodes) is associated with a higher rate of death than gastroesophageal varices as the bleeding is usually more severe.[47] Initial treatment includes volume resuscitation, intravenous vasoactive therapy, and prophylactic antibiotics. In cases of severe hemorrhage, balloon tamponade (using an inflated gastric balloon to apply pressure to the gastroesophageal junction) can be used as a temporizing measure. Endoscopic variceal ligation can be technically challenging depending on the location of the gastric varices. Endoscopic variceal obturation with tissue adhesive (e.g., N-butyl-2-cyanoacrylate, isobutyl-2-cyanoacrylate, or thrombin) is preferred over endoscopic variceal ligation for initial management of bleeding from gastric varices.[48,49] This technique requires special endoscopic expertise, so if it is not available, TIPS can also be used to control the bleeding successfully as first-line therapy or in cases of recurrent bleeding.[50] If a large gastro- splenorenal shunt is present, balloon-occluded retrograde transvenous obliteration (BRTO) can be performed; this involves introducing a balloon catheter into the left renal vein via the jugular or femoral vein and injecting sclerosants or embolic agents to occlude blood flow in the shunt and the varices.[51] There are variations of this procedure, including combination with TIPS—since BRTO increases portal pressure and can lead to the development or worsening of ascites and esophageal varices.[52]

Secondary Prophylaxis of Variceal Bleeding

Persons with cirrhosis who develop variceal bleeding have a 60% risk of rebleeding within 1 year, unless they have treatment for the varices. The risk of dying with each rebleeding episode is approximately 20%.[53,54] Modalities used to prevent rebleeding are considered secondary prophylaxis of variceal bleeding.

Pharmacologic Therapy

Nonselective beta-blockers can reduce the risk of rebleeding by about 40% and improve overall survival by 20%.[55,56,57,58] Adding isosorbide mononitrate to a nonselective beta-blocker may slightly lower the rebleeding rate, but dual medication therapy does not improve mortality and is associated with more side effects[59,60]. Thus, most experts recommend using nonselective beta-blockers without isosorbide mononitrate.[6] Compared with other nonselective beta-blockers, carvedilol has greater effects on hepatic venous pressure gradient and systolic blood pressure. Propranolol and nadolol can be used if there are concerns for systemic hypotension.

Endoscopic Variceal Ligation Therapy

Endoscopic variceal ligation therapy is superior to sclerotherapy for secondary prophylaxis and decreases the rebleeding rate to around 32%.[42] Sessions should be repeated every 7 to 28 days until the varices are eradicated and then EGD should be repeated every 3 to 6 months for surveillance (to determine whether additional endoscopic variceal ligation therapy is required).[6]

Combination Therapy

For secondary prophylaxis of variceal bleeding, the combination of a nonselective beta-blocker and endoscopic variceal ligation therapy is superior to either modality alone; combination therapy decreases the rebleeding rate to about 14 to 23%, although there is no statistical difference in mortality.[58,61] Combination therapy with a nonselective beta-blocker and endoscopic variceal ligation therapy is considered the standard first-line therapy for secondary prophylaxis of variceal bleeding.[6] Thus, in the absence of TIPS placement with the acute episode, persons who received endoscopic variceal ligation therapy should be started on therapy with a nonselective beta-blocker prior to discharge from the hospital.

Transjugular Intrahepatic Portosystemic Shunt

Placement of TIPS has been shown to be superior to endoscopic variceal ligation therapy and pharmacologic therapy in reducing the risk of rebleeding, but with no improvement in mortality and an increase in hepatic encephalopathy.[43,62] If a patient had placement of a TIPS during an acute bleeding episode, they do not need additional therapy for portal hypertension or varices, but they should be referred for liver transplantation evaluation.[6] If a patient has rebleeding after combination therapy with nonselective beta-blockers and endoscopic variceal ligation therapy, placement of a TIPS is the recommended rescue therapy.[6] In clinical practice, the older uncovered TIPS have been replaced by polytetrafluoroethylene-covered TIPS. The patency of the TIPS should be reassessed by Doppler ultrasound every 6 months and from a practical standpoint this evaluation can be coupled with hepatic ultrasound hepatocellular carcinoma surveillance.[6]

Portacaval Shunt Surgery

Surgical placement of a portacaval shunt is effective in preventing rebleeding; this procedure, however, does not improve survival, increases the risk of developing hepatic encephalopathy, and has largely been replaced by TIPS. Portacaval shunt surgery is primarily reserved for persons with Child-Turcotte-Pugh class A liver disease.[4]

Gastric Varices

The combination of a nonselective beta-blocker and endoscopic therapy can be used as secondary variceal hemorrhage prophylaxis for gastroesophageal varices, but for fundal varices, TIPS and/or balloon-occluded retrograde transvenous obliteration can be performed.[63,64]

Summary Points

- Portal hypertension results from increased resistance to portal flow (fixed and dynamic) and increased portal venous blood inflow (splanchnic vasodilatation and increased cardiac output).
- Use of a nonselective beta-blocker, preferably carvedilol, is recommended in patients with compensated cirrhosis and clinically significant portal hypertension. For patients on a nonselective beta-blocker, the need for screening EGD is obviated.
- Patients with clinically significant portal hypertension in whom nonselective beta-blockers are contraindicated or not tolerated should undergo EGD for variceal screening. Persons with compensated cirrhosis can have deferral of EGD if they have liver stiffness measurements of less than 20 kPa (by transient elastography) and platelet counts greater than 150,000/mm^3.
- If EGD is performed and no varices are found, the EGD examination should be repeated in 2 to 3 years or at the time of hepatic decompensation and annually thereafter.
- Small esophageal varices (in the absence of red wale marks or Child-Turcotte-Pugh class C cirrhosis) do not warrant endoscopic variceal ligation, but follow-up EGD should be repeated every 1 to 2 years or at the time of hepatic decompensation.
- Nonselective beta-blockers are recommended for the prevention of the first variceal hemorrhage in those with large esophageal varices or small esophageal varices at high risk of bleeding (red wale marks or Child-Turcotte-Pugh class C cirrhosis). If nonselective beta-blockers are contraindicated or not tolerated, endoscopic variceal ligation can be performed.
- Acute variceal hemorrhage is managed with the combination of an intravenous vasoconstrictor agent, such as octreotide, and endoscopic variceal ligation.
- Early TIPS is recommended in persons at high risk for rebleeding (e.g., CTP class C cirrhosis or CTP class B with active bleeding on endoscopy). Placement of TIPS should also be considered in patients with uncontrolled bleeding or with a rebleed despite vasoactive therapy and endoscopic variceal ligation.
- Bleeding gastric varices can be treated using endoscopic variceal obturation using tissue adhesives, transjugular intrahepatic portosystemic shunt, or balloon-occluded retrograde transvenous obliteration if anatomically feasible.
- In persons who have previously bled, the combination of nonselective beta-blockers and endoscopic variceal ligation reduces the risk of rebleeding. A TIPS procedure decreases the risk of rebleeding further but does not impact survival, so it is reserved for those who fail combination pharmacologic and endoscopic therapy.

Citations

1. Kaplan DE, Bosch J, Ripoll C, et al. AASLD practice guidance on risk stratification and management of portal hypertension and varices in cirrhosis. Hepatology. 2023 Oct 23. Online ahead of print.
[PubMed Abstract] -

2. Brunner F, Berzigotti A, Bosch J. Prevention and treatment of variceal haemorrhage in 2017. Liver Int. 2017;37 Suppl 1:104-115.
[PubMed Abstract] -

3. Garcia-Tsao G, Bosch J. Management of varices and variceal hemorrhage in cirrhosis. N Engl J Med. 2010;362:823-32.
[PubMed Abstract] -

4. Haq I, Tripathi D. Recent advances in the management of variceal bleeding. Gastroenterol Rep (Oxf). 2017;5:113-126.
[PubMed Abstract] -

5. Bosch J, Abraldes JG, Berzigotti A, García-Pagan JC. The clinical use of HVPG measurements in chronic liver disease. Nat Rev Gastroenterol Hepatol. 2009;6:573-82.
[PubMed Abstract] -

6. Garcia-Tsao G, Abraldes JG, Berzigotti A, Bosch J. Portal hypertensive bleeding in cirrhosis: Risk stratification, diagnosis, and management: 2016 practice guidance by the American Association for the study of liver diseases. Hepatology. 2017;65:310-335.
[PubMed Abstract] -

7. Villanueva C, Albillos A, Genescà J, et al. β blockers to prevent decompensation of cirrhosis in patients with clinically significant portal hypertension (PREDESCI): a randomised, double-blind, placebo-controlled, multicentre trial. Lancet. 2019;393:1597-1608.
[PubMed Abstract] -

8. Villanueva C, Torres F, Sarin SK, et al. Carvedilol reduces the risk of decompensation and mortality in patients with compensated cirrhosis in a competing-risk meta-analysis. J Hepatol. 2022;77:1014-25.
[PubMed Abstract] -

9. Jakab SS, Garcia-Tsao G. Screening and Surveillance of Varices in Patients With Cirrhosis. Clin Gastroenterol Hepatol. 2019;17:26-9.
[PubMed Abstract] -

10. Groszmann RJ, Garcia-Tsao G, Bosch J, et al. Beta-blockers to prevent gastroesophageal varices in patients with cirrhosis. N Engl J Med. 2005;353:2254-61.
[PubMed Abstract] -

11. Merli M, Nicolini G, Angeloni S, et al. Incidence and natural history of small esophageal varices in cirrhotic patients. J Hepatol. 2003;38:266-72.
[PubMed Abstract] -

12. D'Amico G, Pagliaro L, Bosch J. Pharmacological treatment of portal hypertension: an evidence-based approach. Semin Liver Dis. 1999;19:475-505.
[PubMed Abstract] -

13. North Italian Endoscopic Club for the Study and Treatment of Esophageal Varices. Prediction of the

first variceal hemorrhage in patients with cirrhosis of the liver and esophageal varices. A prospective multicenter study. N Engl J Med. 1988;319:983-9.
[PubMed Abstract] -

14. Garcia-Tsao G, Sanyal AJ, Grace ND, Carey W; Practice Guidelines Committee of the American Association for the Study of Liver Diseases; Practice Parameters Committee of the American College of Gastroenterology. Prevention and management of gastroesophageal varices and variceal hemorrhage in cirrhosis. Hepatology 2007;46:922-38.
[AASLD Practice Guidelines] -

15. de Franchis R, Pascal JP, Ancona E, et al. Definitions, methodology and therapeutic strategies in portal hypertension. A Consensus Development Workshop, Baveno, Lake Maggiore, Italy, April 5 and 6, 1990. J Hepatol. 1992;15:256-61.
[PubMed Abstract] -

16. Gluud LL, Krag A. Banding ligation versus beta-blockers for primary prevention in oesophageal varices in adults. Cochrane Database Syst Rev. 2012;8:CD004544.
[PubMed Abstract] -

17. Reiberger T, Ulbrich G, Ferlitsch A, et al. Carvedilol for primary prophylaxis of variceal bleeding in cirrhotic patients with haemodynamic non-response to propranolol. Gut. 2013;62:1634-41.
[PubMed Abstract] -

18. Tripathi D, Ferguson JW, Kochar N, et al. Randomized controlled trial of carvedilol versus band ligation for the prevention of the first variceal bleed. Hepatology 2009;50:825-33.
[PubMed Abstract] -

19. Sarin SK, Wadhawan M, Agarwal SR, Tyagi P, Sharma BC. Endoscopic variceal ligation plus propranolol versus endoscopic variceal ligation alone in primary prophylaxis of variceal bleeding. Am J Gastroenterol. 2005;100:797-804.
[PubMed Abstract] -

20. Dave P, Romeu J, Messer J. Upper gastrointestinal bleeding in patients with portal hypertension: a reappraisal. J Clin Gastroenterol. 1983;5:113-5.
[PubMed Abstract] -

21. Naparstek Y, Rachmilewitz D. UGI bleeding in a nonalcoholic population with portal hypertension. J Clin Gastroenterol. 1980;2:239-41.
[PubMed Abstract] -

22. Schoppe LE, Roark GD, Patterson M. Acute upper gastrointestinal bleeding in patients with portal hypertension: a correlation of endoscopic findings with etiology. South Med J. 1983;76:475-6.
[PubMed Abstract] -

23. D'Amico G, De Franchis R; Cooperative Study Group. Upper digestive bleeding in cirrhosis. Post-therapeutic outcome and prognostic indicators. Hepatology. 2003;38:599-612.
[PubMed Abstract] -

24. Carbonell N, Pauwels A, Serfaty L, Fourdan O, Lévy VG, Poupon R. Improved survival after variceal bleeding in patients with cirrhosis over the past two decades. Hepatology. 2004;40:652-9.
[PubMed Abstract] -

25. Krige JE, Kotze UK, Distiller G, Shaw JM, Bornman PC. Predictive factors for rebleeding and death in alcoholic cirrhotic patients with acute variceal bleeding: a multivariate analysis. World J Surg.

2009;33:2127-35.
[PubMed Abstract] -

26. Augustin S, Muntaner L, Altamirano JT, et al. Predicting early mortality after acute variceal hemorrhage based on classification and regression tree analysis. Clin Gastroenterol Hepatol. 2009;7:1347-54.
[PubMed Abstract] -

27. Ben-Ari Z, Cardin F, McCormick AP, Wannamethee G, Burroughs AK. A predictive model for failure to control bleeding during acute variceal haemorrhage. J Hepatol. 1999;31:443-50.
[PubMed Abstract] -

28. Moitinho E, Escorsell A, Bandi JC, et al. Prognostic value of early measurements of portal pressure in acute variceal bleeding. Gastroenterology. 1999;117:626-31.
[PubMed Abstract] -

29. Villanueva C, Colomo A, Bosch A, et al. Transfusion strategies for acute gastrointestinal bleeding. N Engl J Med. 2013;368:11-21.
[PubMed Abstract] -

30. Bosch J, Thabut D, Albillos A, et al. Recombinant factor VIIa for variceal bleeding in patients with advanced cirrhosis: A randomized, controlled trial. Hepatology. 2008;47:1604-14.
[PubMed Abstract] -

31. Bosch J, Thabut D, Bendtsen F, et al. Recombinant factor VIIa for upper gastrointestinal bleeding in patients with cirrhosis: a randomized, double-blind trial. Gastroenterology. 2004;127:1123-30.
[PubMed Abstract] -

32. Simpson E, Lin Y, Stanworth S, Birchall J, Doree C, Hyde C. Recombinant factor VIIa for the prevention and treatment of bleeding in patients without haemophilia. Cochrane Database Syst Rev. 2012;:CD005011.
[PubMed Abstract] -

33. Wells M, Chande N, Adams P, et al. Meta-analysis: vasoactive medications for the management of acute variceal bleeds. Aliment Pharmacol Ther. 2012;35:1267-78.
[PubMed Abstract] -

34. Bhutta AQ, Garcia-Tsao G. The Role of Medical Therapy for Variceal Bleeding. Gastrointest Endosc Clin N Am. 2015;25:479-90.
[PubMed Abstract] -

35. Hung TH, Tsai CC, Tseng CW, Tseng KC, Hsieh YH, Tsai CC. No difference in mortality between terlipressin and somatostatin treatments in cirrhotic patients with esophageal variceal bleeding and renal functional impairment. Eur J Gastroenterol Hepatol. 2016;28:1275-9.
[PubMed Abstract] -

36. Seo YS, Park SY, Kim MY, et al. Lack of difference among terlipressin, somatostatin, and octreotide in the control of acute gastroesophageal variceal hemorrhage. Hepatology. 2014;60:954-63.
[PubMed Abstract] -

37. Bañares R, Albillos A, Rincón D, et al. Endoscopic treatment versus endoscopic plus pharmacologic treatment for acute variceal bleeding: a meta-analysis. Hepatology. 2002;35:609-15.
[PubMed Abstract] -

38. Fernández J, Ruiz del Arbol L, Gomez C, et al. Norfloxacin vs ceftriaxone in the prophylaxis of infections in patients with advanced cirrhosis and hemorrhage. Gastroenterology. 2006;131:1049-56.
[PubMed Abstract] -

39. Runyon BA. Introduction to the revised American Association for the Study of Liver Diseases Practice Guideline management of adult patients with ascites due to cirrhosis 2012. Hepatology. 2013;57:1651-3.
[PubMed Abstract] -

40. Biggins SW, Angeli P, Garcia-Tsao G, et al. Diagnosis, Evaluation, and Management of Ascites, Spontaneous Bacterial Peritonitis and Hepatorenal Syndrome: 2021 Practice Guidance by the American Association for the Study of Liver Diseases. Hepatology. 2021;74:1014-48.
[PubMed Abstract] -

41. D'Amico G, Pagliaro L, Bosch J. The treatment of portal hypertension: a meta-analytic review. Hepatology. 1995;22:332-54.
[PubMed Abstract] -

42. Laine L, Cook D. Endoscopic ligation compared with sclerotherapy for treatment of esophageal variceal bleeding. A meta-analysis. Ann Intern Med. 1995;123:280-7.
[PubMed Abstract] -

43. García-Pagán JC, Caca K, Bureau C, et al. Early use of TIPS in patients with cirrhosis and variceal bleeding. N Engl J Med. 2010;362:2370-9.
[PubMed Abstract] -

44. Monescillo A, Martínez-Lagares F, Ruiz-del-Arbol L, et al. Influence of portal hypertension and its early decompression by TIPS placement on the outcome of variceal bleeding. Hepatology. 2004;40:793-801.
[PubMed Abstract] -

45. Nadler J, Stankovic N, Uber A, et al. Outcomes in variceal hemorrhage following the use of a balloon tamponade device. Am J Emerg Med. 2017;35:1500-1502.
[PubMed Abstract] -

46. Escorsell À, Pavel O, Cárdenas A, et al. Esophageal balloon tamponade versus esophageal stent in controlling acute refractory variceal bleeding: A multicenter randomized, controlled trial. Hepatology. 2016;63:1957-67.
[PubMed Abstract] -

47. Ryan BM, Stockbrugger RW, Ryan JM. A pathophysiologic, gastroenterologic, and radiologic approach to the management of gastric varices. Gastroenterology. 2004;126:1175-89.
[PubMed Abstract] -

48. Lo GH, Lai KH, Cheng JS, Chen MH, Chiang HT. A prospective, randomized trial of butyl cyanoacrylate injection versus band ligation in the management of bleeding gastric varices. Hepatology. 2001;33:1060-4.
[PubMed Abstract] -

49. Tan PC, Hou MC, Lin HC, Liu TT, Lee FY, Chang FY, Lee SD. A randomized trial of endoscopic treatment of acute gastric variceal hemorrhage: N-butyl-2-cyanoacrylate injection versus band ligation. Hepatology. 2006;43:690-7.
[PubMed Abstract] -

50. Chau TN, Patch D, Chan YW, Nagral A, Dick R, Burroughs AK. “Salvage” transjugular intrahepatic

portosystemic shunts: gastric fundal compared with esophageal variceal bleeding. Gastroenterology. 1998;114:981-7.
[PubMed Abstract] -

51. Akahoshi T, Hashizume M, Tomikawa M, et al. Long-term results of balloon-occluded retrograde transvenous obliteration for gastric variceal bleeding and risky gastric varices: a 10-year experience. J Gastroenterol Hepatol. 2008;23:1702-9.
[PubMed Abstract] -

52. Saad WE, Wagner CC, Lippert A, et al. Protective value of TIPS against the development of hydrothorax/ascites and upper gastrointestinal bleeding after balloon-occluded retrograde transvenous obliteration (BRTO). Am J Gastroenterol. 2013;108:1612-9.
[PubMed Abstract] -

53. Bosch J, García-Pagán JC. Prevention of variceal rebleeding. Lancet. 2003;361:952-4.
[PubMed Abstract] -

54. Garcia-Tsao G, Bosch J. Varices and Variceal Hemorrhage in Cirrhosis: A New View of an Old Problem. Clin Gastroenterol Hepatol. 2015;13:2109-17.
[PubMed Abstract] -

55. Pérez-Ayuso RM, Piqué JM, Bosch J, et al. Propranolol in prevention of recurrent bleeding from severe portal hypertensive gastropathy in cirrhosis. Lancet. 1991;337:1431-4.
[PubMed Abstract] -

56. Lebrec D, Poynard T, Hillon P, Benhamou JP. Propranolol for prevention of recurrent gastrointestinal bleeding in patients with cirrhosis: a controlled study. N Engl J Med. 1981;305:1371-4.
[PubMed Abstract] -

57. Hayes PC, Davis JM, Lewis JA, Bouchier IA. Meta-analysis of value of propranolol in prevention of variceal haemorrhage. Lancet. 1990;336:153-6.
[PubMed Abstract] -

58. Kravetz D. Prevention of recurrent esophageal variceal hemorrhage: review and current recommendations. J Clin Gastroenterol. 2007;41 Suppl 3:S318-22.
[PubMed Abstract] -

59. Gluud LL, Langholz E, Krag A. Meta-analysis: isosorbide-mononitrate alone or with either beta-blockers or endoscopic therapy for the management of oesophageal varices. Aliment Pharmacol Ther. 2010;32:859-71.
[PubMed Abstract] -

60. Gournay J, Masliah C, Martin T, Perrin D, Galmiche JP. Isosorbide mononitrate and propranolol compared with propranolol alone for the prevention of variceal rebleeding. Hepatology 2000;31:1239-45.
[PubMed Abstract] -

61. Gonzalez R, Zamora J, Gomez-Camarero J, Molinero LM, Bañares R, Albillos A. Meta-analysis: Combination endoscopic and drug therapy to prevent variceal rebleeding in cirrhosis. Ann Intern Med. 2008;149:109-22.
[PubMed Abstract] -

62. Boyer TD, Haskal ZJ. The Role of Transjugular Intrahepatic Portosystemic Shunt (TIPS) in the Management of Portal Hypertension: update 2009. Hepatology. 2010;51:306.

[PubMed Abstract] -

63. Lo GH, Liang HL, Chen WC, et al. A prospective, randomized controlled trial of transjugular intrahepatic portosystemic shunt versus cyanoacrylate injection in the prevention of gastric variceal rebleeding. Endoscopy. 2007;39:679-85.
[PubMed Abstract] -

64. Saad WE. Balloon-occluded retrograde transvenous obliteration of gastric varices: concept, basic techniques, and outcomes. Semin Intervent Radiol. 2012;29:118-28.
[PubMed Abstract] -

References

- Chawla S, Katz A, Attar BM, Gupta A, Sandhu DS, Agarwal R. Platelet count/spleen diameter ratio to predict the presence of esophageal varices in patients with cirrhosis: a systematic review. Eur J Gastroenterol Hepatol. 2012;24:431-6.
[PubMed Abstract] -

- de Franchis R. Expanding consensus in portal hypertension: Report of the Baveno VI Consensus Workshop: Stratifying risk and individualizing care for portal hypertension. J Hepatol. 2015;63:743-52.
[PubMed Abstract] -

- Garcia-Pagán JC, Di Pascoli M, Caca K, et al. Use of early-TIPS for high-risk variceal bleeding: results of a post-RCT surveillance study. J Hepatol. 2013;58:45-50.
[PubMed Abstract] -

- Garcia-Tsao G, Bosch J, Groszmann RJ. Portal hypertension and variceal bleeding--unresolved issues. Summary of an American Association for the study of liver diseases and European Association for the study of the liver single-topic conference. Hepatology. 2008;47:1764-72.
[AASLD & EASL Summary] -

- Holster IL, Tjwa ET, Moelker A, et al. Covered transjugular intrahepatic portosystemic shunt versus endoscopic therapy + β-blocker for prevention of variceal rebleeding. Hepatology. 2016;63:581-9.
[PubMed Abstract] -

- Li T, Ke W, Sun P, et al. Carvedilol for portal hypertension in cirrhosis: systematic review with meta-analysis. BMJ Open. 2016;6:e010902.
[PubMed Abstract] -

- Lim JK, Flamm SL, Singh S, Falck-Ytter YT. American Gastroenterological Association Institute Guideline on the Role of Elastography in the Evaluation of Liver Fibrosis. Gastroenterology. 2017;152:1536-1543.
[PubMed Abstract] -

- Mandorfer M, Reiberger T. Beta blockers and cirrhosis, 2016. Dig Liver Dis. 2017;49:3-10.
[PubMed Abstract] -

- McCarty TR, Afinogenova Y, Njei B. Use of Wireless Capsule Endoscopy for the Diagnosis and Grading of Esophageal Varices in Patients With Portal Hypertension: A Systematic Review and Meta-Analysis. J Clin Gastroenterol. 2017;51:174-182.
[PubMed Abstract] -

- Rudler M, Cluzel P, Corvec TL, et al. Early-TIPSS placement prevents rebleeding in high-risk patients

with variceal bleeding, without improving survival. Aliment Pharmacol Ther. 2014;40:1074-80. [PubMed Abstract] -

- Schwarzenberger E, Meyer T, Golla V, Sahdala NP, Min AD. Utilization of platelet count spleen diameter ratio in predicting the presence of esophageal varices in patients with cirrhosis. J Clin Gastroenterol. 2010;44:146-50. [PubMed Abstract] -

Figures

Figure 1 Prognostic Value of Hepatic Venous Pressure Gradient (HVPG) in Persons with Chronic Liver Disease

Abbreviations: HVPG = hepatic venous portal gradient

Source: modified from Bosch J, Abraldes JG, Berzigotti A, García-Pagan JC. The clinical use of HVPG measurements in chronic liver disease. Nat Rev Gastroenterol Hepatol. 2009;6:573-82.

Prognostic Value of HVPG in Patients with Chronic Liver Disease

Measurement	Significance
1-5 mm Hg	Normal
≥ 6 mm Hg	Risk of disease progression in persons with HCV recurrence after liver transplantation
≥ 10 mm Hg	Clinically significant portal hypertension
≥ 12 mm Hg	Increased risk for rupture of varices
≥ 16 mm Hg	Increased risk of mortality
≥ 20 mm Hg	Treatment failure and mortality in acute variceal bleeding

Figure 2 Cirrhotic Liver without Esophageal Varices

The left side of the illustration shows moderately advanced cirrhosis. The inset shows an internal longitudinal view of the esophagus, with absence of esophageal varices. The far right inset shows the esophageal view as seen from the operator of the endoscope.

Illustration by Cognition Studio, Inc.

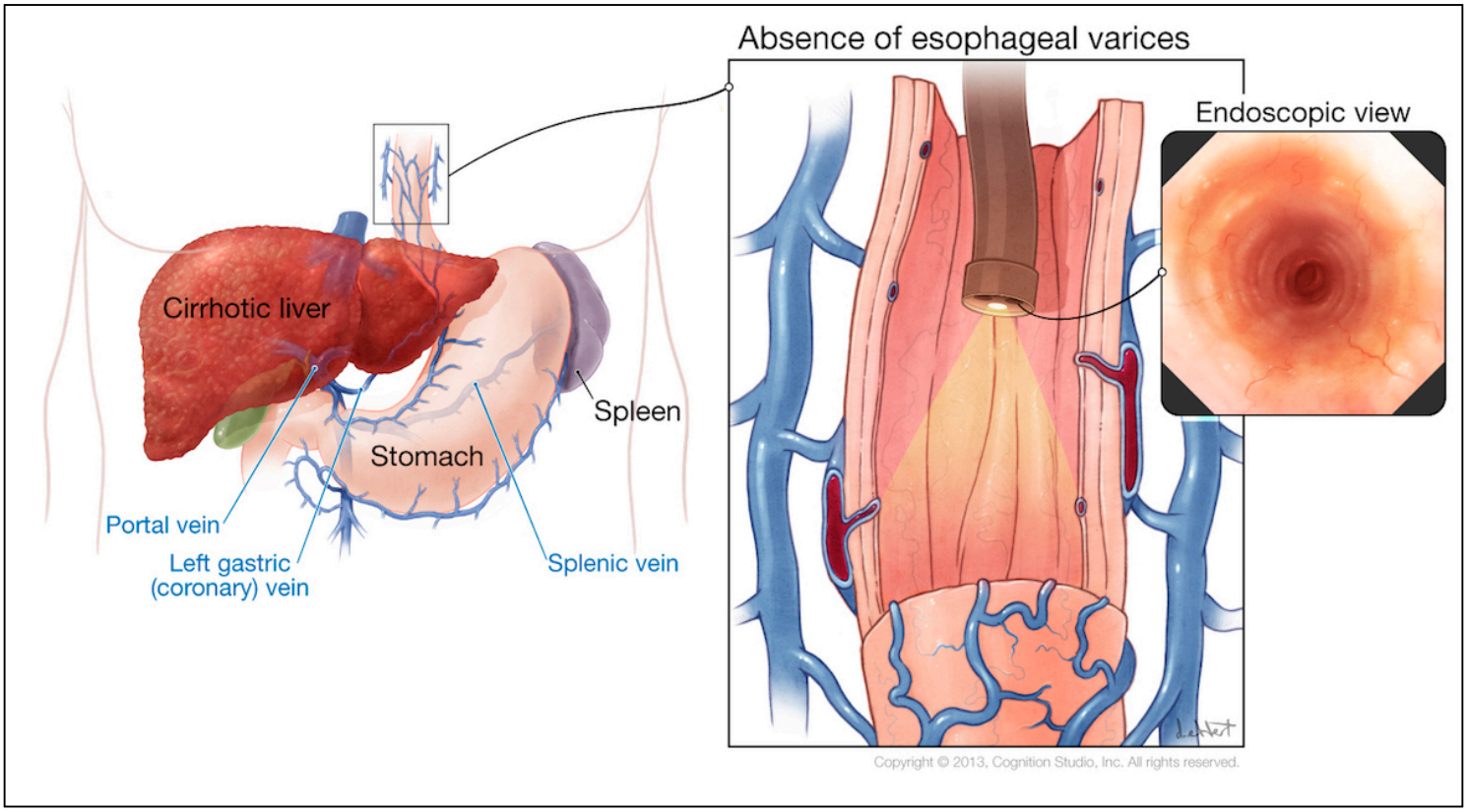

Figure 3 Cirrhotic Liver with Esophageal Varices

The left side of the illustration shows advanced cirrhosis and marked dilatation of surrounding veins. The inset shows an internal longitudinal view of the esophagus, with the presence of esophageal varices. The far right inset shows the esophageal view of the visible varices as seen from the operator of the endoscope.

Illustration by Cognition Studio, Inc.

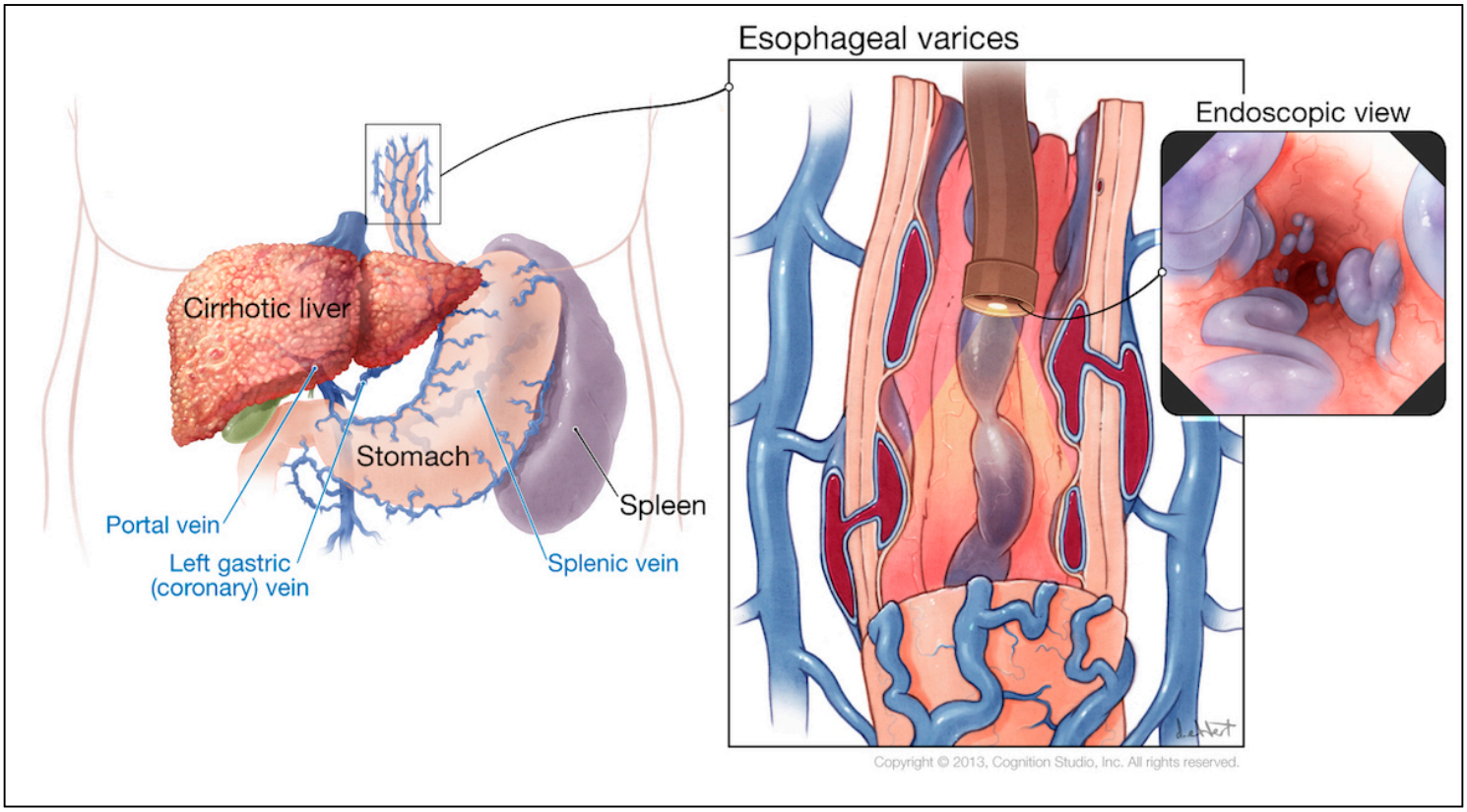

Figure 4 Management of Persons with Cirrhosis Following EGD Screening

Abbreviation: EGD = esophagogastroduodenoscopy
^The 2-year interval is recommended in persons who have ongoing liver injury or associated comorbidities, such as obesity or alcohol use. The 3-year interval is appropriate when the liver injury is considered quiescent, such as following viral elimination or abstinence from alcohol.
+Persons with small varices not on a recommended beta-blocker should have endoscopy repeated every year (with ongoing liver injury) or every 2 years (if liver injury is quiescent)

Source: this figure is based on recommendation from Garcia-Tsao G, Abraldes JG, Berzigotti A, Bosch J. Portal hypertensive bleeding in cirrhosis: Risk stratification, diagnosis, and management: 2016 practice guidance by the American Association for the study of liver diseases. Hepatology. 2017;65:310-35.

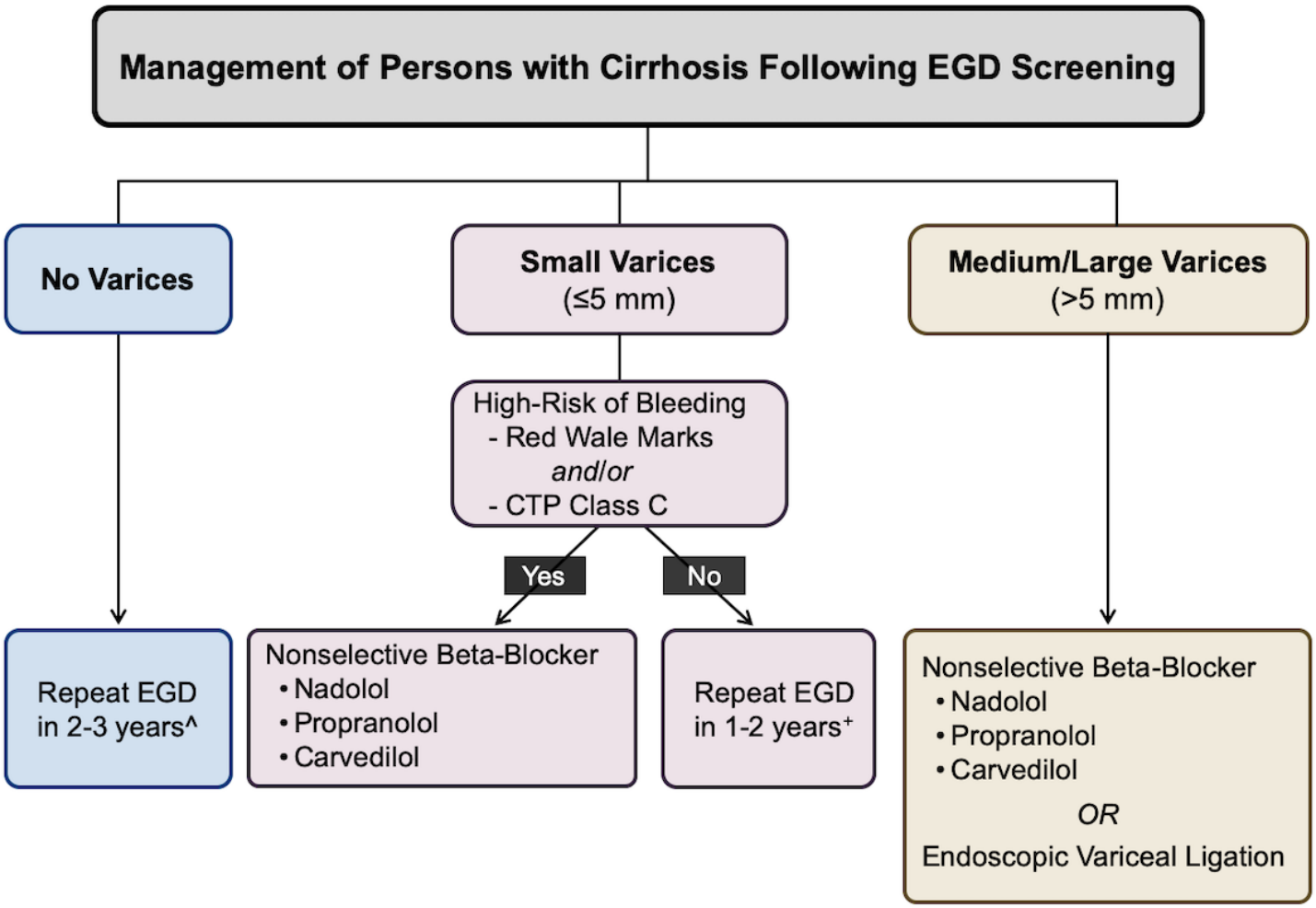

Figure 5 Endoscopic View of Small Esophageal Varices

Endoscopic view of the esophagus, looking down into the esophageal lumen. The white arrows indicate the presence of small esophageal varices.

Photograph courtesy of Dr. Iris Liou, University of Washington.

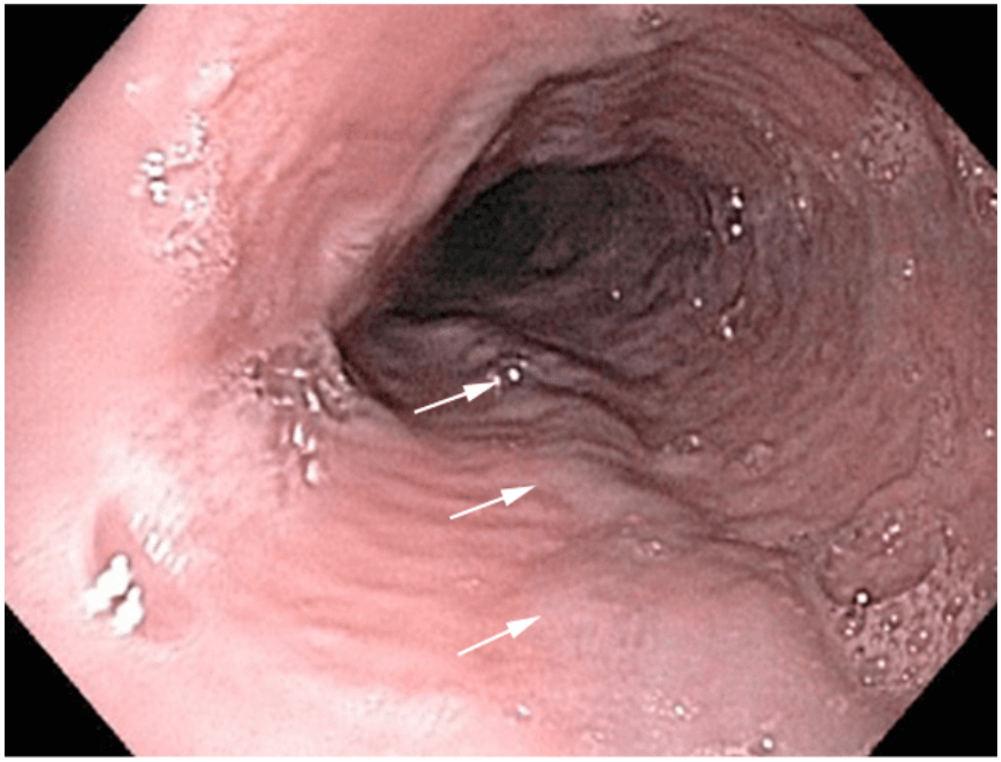

Figure 6 Endoscopic View of Large Esophageal Varices

Endoscopic view of the esophagus, looking down into the esophageal lumen. The white arrows indicate the presence of two columns of large esophageal varices.

Photograph courtesy of Dr. Iris Liou, University of Washington.

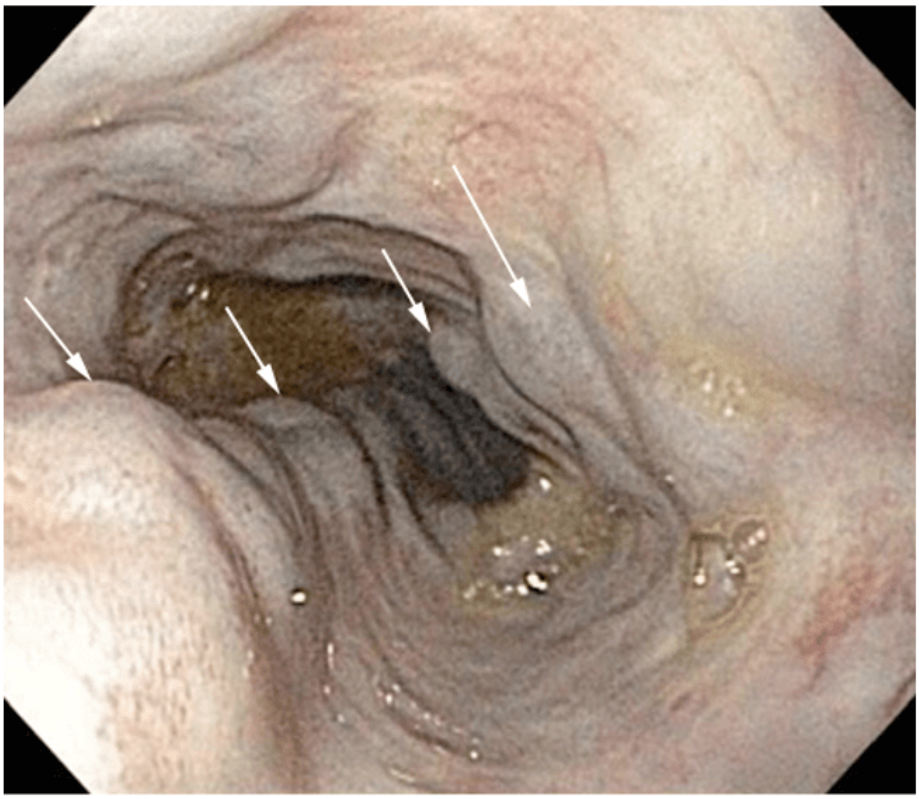

Figure 7 Nonselective Beta-Blockers for Primary Prophylaxis against Variceal Bleeding

All medications listed are oral regimens.

Source: modified from Kaplan DE, Bosch J, Ripoll C, et al. AASLD practice guidance on risk stratification and management of portal hypertension and varices in cirrhosis. Hepatology. 2023 Oct 23. Online ahead of print.

Recommended Beta-Blockers for Primary Prophylaxis Against Variceal Bleeding

Therapy	Starting Dose	Dose Titration	Maximal Dose	Goal
Carvedilol	6.25 mg once daily	After 3 days, increase to 6.25 mg twice daily	12.5 mg/day (higher doses could be considered for nonhepatic indication)	No heart rate goal Maintain systolic blood pressure ≥90 mm Hg
Nadolol	20 to 40 mg at bedtime		• Without ascites: 160 mg/day • With ascites: 80 mg/day	
Propanolol	20 to 40 mg twice daily	Increase every 2-3 days until treatment goal	• Without ascites: 320 mg/day • With ascites: 160 mg/day	• Heart rate 55-60 beats per minute • Maintain systolic blood pressure ≥90 mm Hg

Table 1.

Vasoactive Agents for Acute Variceal Bleeding

Agent	Dosing	Duration
Octreotide	Initial i.v. bolus of 50 mcg and continue infusion at a rate of 25-50 mcg/hour	2-5 days
Somatastatin	Initial i.v. bolus of 250 mcg and continue infusion at a rate of 250-500 mcg/hour	2-5 days
Terlipressin*	Initial 24-48 hours: 2 mg i.v. every 4-6 hours and then 1 mg i.v. every 4-6 hours	2-5 days
*Not approved for this indication in North America		

Source:

- Garcia-Tsao G, Abraldes JG, Berzigotti A, Bosch J. Portal hypertensive bleeding in cirrhosis: Risk stratification, diagnosis, and management: 2016 practice guidance by the American Association for the study of liver diseases. Hepatology. 2017;65:310-335. [PubMed Abstract]
- Kaplan DE, Bosch J, Ripoll C, et al. AASLD practice guidance on risk stratification and management of portal hypertension and varices in cirrhosis. Hepatology. 2023 Oct 23. Online ahead of print. [PubMed Abstract]
- Seo YS, Park SY, Kim MY, et al. Lack of difference among terlipressin, somatostatin, and octreotide in the control of acute gastroesophageal variceal hemorrhage. Hepatology. 2014;60:954-63. [PubMed Abstract]