

Evaluation and Staging of Liver Fibrosis

This is a PDF version of the following document:

Module 2: [Evaluation, Staging, and Monitoring of Chronic Hepatitis C](#)

Lesson 4: [Evaluation and Staging of Liver Fibrosis](#)

You can always find the most up-to-date version of this document at

<https://www.hepatitisC.uw.edu/go/evaluation-staging-monitoring/evaluation-staging/core-concept/all>.

Background

Pathogenesis of Fibrosis with Chronic HCV Infection

Hepatic fibrosis is a dynamic scarring process in which chronic inflammation stimulates production and accumulation of collagen and extracellular matrix proteins.[1,2] The hepatic stellate cells are the primary cells responsible for producing these extracellular matrix proteins. Over time, with chronic hepatitis C virus (HCV) infection, the total extracellular matrix protein content increases, and fibrosis can develop, with potential progression to cirrhosis.[3] This dynamic process can also involve remodeling and regression of the fibrous tissue via breakdown of the matrix proteins by the protease enzymes matrix metalloproteinases (MMP).[2,4]

General Approach to Evaluating Liver Fibrosis

Fibrosis is a precursor to cirrhosis, and establishing the severity of liver fibrosis helps predict liver-related morbidity and mortality, as well as to inform the need for hepatocellular carcinoma (HCC) screening in persons with chronic HCV. Noninvasive methods to estimate hepatic fibrosis are commonly used in clinical practice as a safer, more accessible, and less costly strategy than liver biopsy for stratifying persons according to risk.[5,6,7] These methods include indirect biomarkers, direct biomarkers, and elastography.[7,8,9] If a combination of noninvasive methods provides a clear-cut assessment of hepatic fibrosis, further assessment with liver biopsy is generally not needed.[10,11] Although liver biopsy with histologic analysis has long been considered the gold standard evaluation of hepatic fibrosis, it is now infrequently used for evaluation of liver fibrosis in persons with chronic HCV.[12] In the current era, the optimal approach to fibrosis assessment is to use noninvasive serum markers/tests in conjunction with transient elastography. If transient elastography is not available, two different noninvasive serum markers/tests should be used.

Indirect Markers for Estimating Hepatic Fibrosis

In recent years, the use of noninvasive (both indirect and direct) measures of fibrosis has become commonplace in clinical practice. Initial screening with simple laboratory tests, such as platelet count, prothrombin time, albumin, total bilirubin, and serum aminotransferase levels, are commonly performed to estimate fibrosis and identify cirrhosis. Different combinations of these measures have been used to estimate the degree of hepatic fibrosis in persons with chronic HCV. Additional serum markers of fibrosis, such as hyaluronic acid (HA) and alpha-2-macroglobulin, are less readily available and have been utilized primarily in tests that include panels of such markers, often combined with standard clinical liver tests.

Commonly Used Indirect Markers for Hepatic Fibrosis

Aspartate Aminotransferase-to-Platelet Ratio Index (APRI)

The APRI model was developed as a simple, easily calculated method to predict significant, severe fibrosis (or cirrhosis) and has been tested in persons with HCV mono-infection and those with HCV and HIV coinfection.[\[13,14\]](#) The APRI is calculated using the individual's aspartate aminotransferase (AST) level, corrected for the upper limit of normal, and platelet count ([Figure 1](#)). A meta-analysis of 40 studies found that an APRI cutoff of greater than or equal to 0.7 had an estimated sensitivity of 77% and specificity of 72% for detection of significant hepatic fibrosis (greater than or equal to F2 by Metavir) in persons with chronic HCV.[\[15\]](#) A cutoff score of at least 1.0 has an estimated sensitivity of 61 to 76% and specificity of 64 to 72% for detection of severe fibrosis/cirrhosis (F3 to F4 by Metavir). For detection of cirrhosis, a cutoff score of at least 2.0 was more specific (91%) but less sensitive (46%). Overall, APRI has good diagnostic utility for predicting severe fibrosis/cirrhosis or low risk of significant fibrosis, but does not accurately differentiate intermediate stages of fibrosis from mild or severe fibrosis. Thus, clinicians should use APRI in combination with other noninvasive markers of fibrosis, rather than as the sole method of staging.[\[16\]](#)

FIB-4

The FIB-4 is a widely used index based on readily available routine laboratory values and has been shown to have good performance characteristics for estimating hepatic fibrosis in large observational cohorts, including in persons with HCV and HIV coinfection.[\[17,18,19\]](#) Results are generated utilizing age, AST, alanine aminotransferase (ALT), and platelet count ([Figure 2](#)). A threshold value of less than 1.45 has a sensitivity of 74% and a negative predictive value of 95% for excluding advanced fibrosis (F3-F4).[\[20\]](#) A threshold value greater than 3.25 has a positive predictive value for advanced fibrosis of 65 to 82%, with a specificity of 98% in confirming cirrhosis.[\[18,20\]](#) This model was good at excluding or confirming cirrhosis, but values between 1.45 and 3.25 did not fully discriminate fibrosis and would need an additional method to predict liver fibrosis.[\[16\]](#) The AASLD-IDSA HCV Guidance considers a patient with chronic HCV is presumed to have cirrhosis if they have a FIB-4 score of greater than 3.25.[\[21,22,23\]](#)

FibroTest and ActiTest

The HCV FibroTest and ActiTest are used for the assessment of liver fibrosis and inflammation, respectively.

- **FibroTest:** The FibroTest uses a proprietary algorithm that includes the individual's age and gender, along with a composite of five biochemical markers associated with hepatic fibrosis: alpha-2-macroglobulin, haptoglobin, gamma-glutamyltransferase (GGT), apolipoprotein A1, and total bilirubin. The FibroTest estimates hepatic fibrosis. In one meta-analysis of 30 studies with over 2,400 individual-level data, the FibroTest was found to be a reasonable alternative to biopsy for distinguishing moderate to higher fibrosis stages (F2-F4) from mild disease stages, with a mean standardized area under the receiver-operating characteristics (AUROC) curve of 85% for chronic HCV.[\[24\]](#)
- **ActiTest:** The ActiTest uses a second algorithm that adds a direct marker for inflammatory activity

(the ALT value) to the same five parameters in the FibroTest. The ActiTest estimates hepatic inflammation (necroinflammation activity grade).[25]

- **FibroSure Test/FibroTest-ActiTest:** Commercially, the FibroTest and ActiTest are typically obtained as a combination test and referred to as the FibroSure Test or the FibroTest-ActiTest. Like other biomarkers, this test is indeterminate for discriminating the middle ranges, and an adjunct marker of fibrosis would be needed in those situations. Contraindications or cautions for use of these methods for fibrosis staging include the presence of any of the following: Gilbert's disease, acute hemolysis, acute liver inflammation, extrahepatic cholestasis, renal insufficiency, posttransplantation, or receipt of medications that may cause unconjugated hyperbilirubinemia. All of these conditions may lead to inaccurate quantitative predictions. The HCV FibroTest-ActiTest is not approved by the Food and Drug Administration (FDA), but is available through LabCorp and the Mayo Clinic.

Less Commonly Used Markers for Hepatic Fibrosis

FibroIndex

The FibroIndex is a simple scoring method consisting of three biochemical markers: AST, platelet count, and gamma globulin (Figure 3).[26] When a cutoff of less than or equal to 1.25 was used, the sensitivity was 40% and specificity 94% for mild fibrosis (F0 or F1 by Metavir). When a cutoff of greater than or equal to 2.25, the sensitivity was 36% and specificity 97% for significant fibrosis (F2 or F3 by Metavir). Persons with F4 fibrosis were not included in the validation study. The FibroIndex has good specificity but low sensitivity for determining mild or significant fibrosis. Because of this low sensitivity, the FibroIndex is not an adequate tool to be used alone but may serve as an adjunct along with other fibrosis markers.

Forns Index

The Forns Index uses simply obtained parameters—age, GGT, cholesterol, and platelet count—but requires a relatively complicated calculation (Figure 4).[27] A cutoff score of less than 4.25 had a negative predictive value of 96% for excluding significant fibrosis (F2, F3, or F4). At a cutoff of greater than 6.9, the positive predictive value was 66% for significant fibrosis (F2, F3, or F4). This tool is useful and has good predictive value in identifying those with a low risk of significant fibrosis, but it does not reliably predict more advanced fibrosis or cirrhosis. Due to varying cholesterol levels that occur in persons with HCV genotype 3, this method should not be used in these individuals.[28] This method, along with other serum biomarkers, has also been studied as a predictive tool to evaluate fibrosis regression in response to HCV therapy, and for fibrosis assessment in persons with HIV and HCV coinfection, with comparable predictive value to persons with HCV mono-infection.[29,30]

HepaScore

The HepaScore was designed to improve upon nonspecific marker indices in fibrosis models by adding fibrosis-specific markers (age, sex, total bilirubin, GGT, alpha-2-macroglobulin, and hyaluronic acid levels).[31] The HepaScore algorithm is more complicated than other indirect markers, and the laboratory performing the test utilizes a complex modeling equation to generate the result (Figure 5). At values less than or equal to 0.2, the negative predictive value to exclude fibrosis is 98%. At values greater than or equal to 0.8, the positive predictive value for predicting cirrhosis is 62%. Given the good negative predictive value with a low HepaScore, this method is reliable for excluding significant fibrosis but not as good at predicting cirrhosis. For a HepaScore of greater than 0.2, an adjunct marker of fibrosis should be used to predict cirrhosis.

Direct Markers of Fibrosis

Direct markers of fibrosis include procollagen type (I, III, IV), matrix metalloproteinases, cytokines, and chemokines. The direct markers have shown variable effectiveness in predicting liver fibrosis. Among these markers, those currently used involve matrix metalloproteinases. Liver fibrosis/cirrhosis is characterized by enhanced extracellular matrix synthesis by activated stellate cells.[\[1,2\]](#) Matrix metalloproteinases are endopeptidases that can degrade collagen and are involved in the tissue remodeling process that takes place with fibrosis.[\[1\]](#) Levels of matrix metalloproteinases are regulated by specific tissue inhibitors of metalloproteinase (TIMPs) and a mismatch between these inhibitors is associated with extracellular matrix deposition and breakdown. Levels of TIMP-1 significantly correlate with fibrosis, with a sensitivity of 100% in diagnosing cirrhosis, but these tests have low specificity. Hyaluronic acid is a glycosaminoglycan secreted by hepatic stellate cells and is one of the chief components of the extracellular matrix. Extensive fibrosis/cirrhosis has been found to be associated with increased serum levels of hyaluronic acid.[\[32\]](#)

FIBROSpect II

The FIBROSpect II is a commercially available test that combines hyaluronic acid, tissue inhibitor of a metalloproteinase-1 (TIMP-1), and alpha-2-macroglobulin in a predictive algorithm for fibrosis stages F2 to F4. An index score of greater than 0.42 correlates with the presence of stage F2 to F4 fibrosis. Based on data from the test manufacturer involving 696 persons with chronic HCV infection, the overall sensitivity at this cutoff is 80.6% and the specificity 71.4%.[\[33\]](#) Overall, similar to the noninvasive serum markers of fibrosis, the FIBROSpect II test is good for determining the presence or absence of significant fibrosis, but not useful in differentiating among intermediate stages of fibrosis.[\[34\]](#) The HCV FIBROSpect II is not approved by the Food and Drug Administration.

Radiologic Modalities to Estimate Fibrosis

Transient Elastography

Transient elastography (FibroScan) is a noninvasive, easy-to-perform office-based test that takes about 5 to 10 minutes; this test can be done in the clinic or office-based setting.[35] Transient elastography examines a larger area of liver tissue (1 cm diameter by 5 cm in length) than liver biopsy and thus may provide a more representative assessment of the entire hepatic parenchyma. The test is performed using an ultrasound transducer probe that measures the shear wave velocity, which correlates directly with liver stiffness. Transient elastography was approved by the United States FDA in 2013 and has largely replaced liver biopsy as the preferred method for liver fibrosis staging in chronic HCV.

- **Transient Elastography Cutoff Values:** In 2005, Castera published findings for optimal transient elastography cutoff values that correlate with Metavir fibrosis scores (Figure 6).[36,37,38] This study of transient elastography found when liver stiffness values range between 2.5 and 7 kPa, mild or absent fibrosis is likely (F0-F1), scores between 7.1-9.5 correlated with significant fibrosis, scores between 9.6-12.5 indicated severe fibrosis (F3), whereas liver stiffness values above 12.5 kPa indicated cirrhosis (F4) is likely. Using a Castera study, a cutoff of 12.5 kPa (transient elastography score greater than 12.5 kPa), the diagnostic performance for cirrhosis in persons with chronic HCV was high, with a sensitivity of 87%, specificity of 91%, positive predictive value of 0.77, and a negative predictive value of 0.95. The AASLD-IDSA HCV Guidance considers a transient elastography score greater than 12.5 kPa as indicative of cirrhosis in patients with chronic HCV.[21,22,23]
- **Factors that Impact Transient Elastography:** It is important to note that in clinical practice, multiple factors, such as hepatic inflammation, obesity, ingestion of a meal within 2 hours of the test, ascites, and elevated central venous pressure, can influence the transient elastography result. In addition, use of transient elastography is not advised to stage fibrosis in pregnant women since pregnancy can be associated with a reversible increase in liver stiffness.[39]
- **Contraindications for Transient Elastography:** Transient elastography is contraindicated in those with pacemakers and implantable defibrillators.
- **Performance of Transient Elastography:** Studies evaluating transient elastography have demonstrated reproducible performance across a variety of patient populations, including in persons with chronic HCV.[40,41,42] Most experts consider transient elastography as the most accurate noninvasive test for identifying Metavir Stage F3 fibrosis or cirrhosis, but in clinical practice, it is typically used in conjunction with other indirect or direct measures of hepatic fibrosis.

Shear Wave Elastography

Shear wave elastography (ShearWave Elastography), otherwise known as ultrasound elastography, is a noninvasive sonographic test that can estimate hepatic fibrosis. The test is performed by watching a real-time image with B-mode ultrasound, and then measuring liver stiffness based on anatomical information; the test also can assess liver homogeneity based on the color images it generates that correlates with varying degrees of liver stiffness.[43,44] Based on limited data, shear wave elastography performs with similar accuracy as transient elastography in estimating hepatic fibrosis.[43,44] In the United States, shear wave elastography is used much less frequently than transient elastography.

Hepatic Ultrasound

Hepatic ultrasound is a noninvasive and reproducible technique for determining focal and parenchymal disease of the liver. Ultrasound can potentially identify various factors that are useful in evaluating chronic liver disease: nodularity of the liver surface (which reflects the presence of regenerative nodules and fibrous septa often seen in cirrhosis), coarseness of the parenchyma, patency and flow of veins and arteries, spleen size (which, if enlarged, can suggest portal hypertension), hepatocellular carcinoma, and small volume ascites. The use of high-frequency ultrasound transducers is reported to be more reliable than low-frequency

ultrasound in diagnosing cirrhosis.[45] In general, though, a standard ultrasound has been shown to have low sensitivity (in the range of 40%) for the detection of cirrhosis.[46] In addition, false-positive readings by radiologists can occur, particularly in the absence of more conclusive findings of portal hypertension (e.g., coarse echotexture without splenomegaly).[47] Given the limitations noted above, hepatic ultrasound is not recommended routinely for liver disease staging.

Magnetic Resonance Elastography

Magnetic resonance elastography involves applying a probe to a person's back, emitting low-frequency vibrations through the liver, which then are measured through magnetic resonance imaging spin echo sequence. A meta-analysis of five trials comparing magnetic resonance elastography to liver biopsies showed a sensitivity of 94% and specificity of 95% in differentiating F0 to F1 from F2 to F4, as well as a sensitivity of 98% and specificity of 94% in differentiating F0 to F3 from F4.[48] This technique shares the same limitations as transient elastography and is less widely available.[49,50]

Computed Tomography

Morphologic changes related to cirrhosis to the liver can be detected on computed tomography (CT) scan at later stages, but CT, like ultrasound, is not considered sufficiently sensitive for detecting less advanced stages of fibrosis.[51] Newer modalities, such as perfusion CT and software using artificial intelligence, may offer alternative and more sensitive options for staging fibrosis in the future.

Liver Biopsy and Histologic Assessment of the Liver

Liver Biopsy

Liver biopsy is considered the gold standard for diagnosing and assessing liver fibrosis.[12,52] Although liver biopsy is infrequently used to stage fibrosis in clinical practice, there are several advantages to this modality for fibrosis staging when compared to non-invasive testing. For one, a liver biopsy provides information on both the grade (degree of inflammation that reflects ongoing liver disease injury) and the stage (amount of currently established fibrosis) of liver fibrosis. Second, liver biopsy can provide helpful diagnostic information when other factors, such as alcohol consumption, chronic hepatitis B virus (HBV) infection, increased iron stores, or metabolic dysfunction-associated steatotic liver disease (MASLD), may be contributing to accelerated fibrosis progression.[53] Given that potential liver injury related to any of these factors is best assessed by histology, their presence may contribute to the clinical decision-making process regarding the need for liver biopsy. There are several limitations to the use of liver biopsy that have curtailed its use for assessing fibrosis: (1) persons undergoing liver biopsy may experience significant pain with the procedure, (2) it may be associated with risk of bleeding, and (3) even under ideal circumstances, liver biopsy may incorrectly stage fibrosis 20% of the time due to sampling error and/or interobserver variability.[31,54,55,56,57] Noninvasive methods for assessing fibrosis have replaced liver biopsy for the routine assessment of fibrosis severity in persons with chronic HCV.[58]&

Indications for Liver Biopsy

Prior to the development of widely used noninvasive tests that estimate hepatic fibrosis, such as aspartate aminotransferase-to-platelet ratio index (APRI), FibroSure, FibroTest, and transient elastography (FibroScan), liver biopsy was used to estimate liver fibrosis. Traditionally, the primary reasons for doing a liver biopsy have been to (1) provide information on fibrosis stage, which can help guide therapeutic HCV management decisions, (2) diagnose coexisting liver diseases, and (3) help identify cirrhosis (or advanced fibrosis) that would necessitate routine cancer surveillance. In the current era, liver biopsy is used less frequently. The following outlines certain circumstances that may warrant consideration of liver biopsy when evaluating a person with chronic HCV.

- Two indirect markers (such as FibroTest and APRI) show discordant results. For example, when an APRI score is in the 0.5 to 1.5 range, and the FibroSure/FibroTest is less than 0.48, then a liver biopsy may be warranted to determine the presence or absence of advanced fibrosis/cirrhosis and the need for routine hepatocellular cancer surveillance and follow-up. This is most relevant when there is no access to transient elastography.
- There is a second cause of liver disease suspected.
- Indirect, direct, and transient elastography tests are unavailable or not advisable for specific reasons.

Approaches to Liver Biopsy

There are three ways to obtain a liver biopsy: (1) percutaneous (often with ultrasound guidance), (2) transjugular or transfemoral, and (3) laparoscopic. The percutaneous route is the most commonly performed biopsy method in most settings. Specimens are obtained either with a core aspiration needle or sheathed cutting needle that is at least 16-gauge in caliber. The optimum size of a specimen that offers the least risk of understaging fibrosis is 3 cm in length after formalin fixation, and the sample should include at least 11 portal tracts. The number of portal tracts is relative to biopsy size, and, generally, samples greater than 2 cm in length are acceptable.[59] In most circumstances, liver biopsy can be done with minimal side effects, but pain and bleeding can occur.[60]

Classification of Liver Histology

Several histologic scoring systems have been developed to grade (inflammation) and stage (fibrosis) hepatic

disease caused by hepatitis ([Figure 7](#)).[\[59,61,62\]](#) More complex scoring systems, such as Knodell or Ishak, are generally limited to use in research, including clinical trials.[\[63,64\]](#) For clinical purposes, scoring systems with fewer grade and stage categories are generally utilized; these include Batts and Ludwig, Metavir, and International Association for Study of the Liver (IASL).[\[54,65\]](#) The main determinants of inflammatory activity are lymphocytic piecemeal necrosis, lobular necroinflammation, and portal inflammation, which are graded 0 to 4 in most classification systems. The main determinant of fibrosis is the degree of expansion of fibrotic areas between portal tracts, and these changes are staged 0 to 4 in the classification systems commonly used in clinical practice. Fragmentation of the biopsy sample, which can occur more extensively with advanced stages of fibrosis, may also suggest septal or bridging fibrosis (stage 3-4 disease).[\[66\]](#)

Summary Points

- HCV-related hepatic fibrosis is a dynamic scarring process in which chronic inflammation stimulates production and accumulation of collagen and extracellular matrix proteins.
- Hepatic fibrosis is a precursor to cirrhosis and establishing the severity of liver fibrosis helps predict liver-related morbidity and mortality.
- Simple laboratory tests should continue to be utilized to identify overt cirrhosis, in conjunction with abdominal imaging where appropriate.
- Liver biopsy remains the gold standard for diagnosing other causes of liver disease and for establishing the presence and severity of fibrosis.
- Noninvasive serum markers show clinical utility in predicting presence or absence of significant fibrosis/cirrhosis, but are not as useful in differentiating between intermediate stages of fibrosis.
- In general, the optimal approach to fibrosis assessment is to use noninvasive serum markers/tests in conjunction with transient elastography. If transient elastography is not available then two different noninvasive serum markers/tests should be used.
- Relatively little experience exists with the use of direct serum markers and the clinical utility of these markers remains less well-defined when compared with other markers.
- Among the noninvasive tests used to evaluate liver fibrosis, transient elastography is one of the most accurate for identifying cirrhosis.
- Magnetic resonance elastography has also been shown to be highly accurate in estimating hepatic fibrosis, but this test is less widely available.

Citations

1. Friedman SL. Evolving challenges in hepatic fibrosis. Nat Rev Gastroenterol Hepatol. 2010;7:425-36.
[\[PubMed Abstract\]](#) -
2. Hernandez-Gea V, Friedman SL. Pathogenesis of liver fibrosis. Annu Rev Pathol. 2011;6:425-56.
[\[PubMed Abstract\]](#) -
3. Pinzani M. Pathophysiology of Liver Fibrosis. Dig Dis. 2015;33:492-7.
[\[PubMed Abstract\]](#) -
4. Seki E, Brenner DA. Recent advancement of molecular mechanisms of liver fibrosis. J Hepatobiliary Pancreat Sci. 2015;22:512-8.
[\[PubMed Abstract\]](#) -
5. Sharma S, Khalili K, Nguyen GC. Non-invasive diagnosis of advanced fibrosis and cirrhosis. World J Gastroenterol. 2014;20:16820-30.
[\[PubMed Abstract\]](#) -
6. AASLD-IDSA. HCV Guidance: Recommendations for testing, management, and treating hepatitis C. When and in whom to initiate HCV therapy.
[\[AASLD-IDSA Hepatitis C Guidance\]](#) -
7. Chou R, Wasson N. Blood tests to diagnose fibrosis or cirrhosis in patients with chronic hepatitis C virus infection: a systematic review. Ann Intern Med. 2013;158:807-20.
[\[PubMed Abstract\]](#) -
8. van Katwyk S, Coyle D, Cooper C, et al. Transient elastography for the diagnosis of liver fibrosis: a systematic review of economic evaluations. Liver Int. 2017;37:851-861.
[\[PubMed Abstract\]](#) -
9. Carlson JJ, Kowdley KV, Sullivan SD, Ramsey SD, Veenstra DL. An evaluation of the potential cost-effectiveness of non-invasive testing strategies in the diagnosis of significant liver fibrosis. J Gastroenterol Hepatol. 2009;24:786-91.
[\[PubMed Abstract\]](#) -
10. Boursier J, de Ledinghen V, Zarski JP, et al. Comparison of eight diagnostic algorithms for liver fibrosis in hepatitis C: new algorithms are more precise and entirely noninvasive. Hepatology. 2012;55:58-67.
[\[PubMed Abstract\]](#) -
11. Duarte-Rojo A, Altamirano JT, Feld JJ. Noninvasive markers of fibrosis: key concepts for improving accuracy in daily clinical practice. Ann Hepatol. 2012;11:426-39.
[\[PubMed Abstract\]](#) -
12. Rockey DC, Caldwell SH, Goodman ZD, Nelson RC, Smith AD; American Association for the Study of Liver Diseases. Liver biopsy. Hepatology. 2009;49:1017-44.
[\[PubMed Abstract\]](#) -
13. Wai CT, Greenson JK, Fontana RJ, Kalbfleisch JD, Marrero JA, Conjeevaram HS, Lok AS. A simple noninvasive index can predict both significant fibrosis and cirrhosis in patients with chronic hepatitis C. Hepatology. 2003;38:518-26.
[\[PubMed Abstract\]](#) -

14. Schmid P, Bregenzer A, Huber M, et al. Progression of Liver Fibrosis in HIV/HCV Co-Infection: A Comparison between Non-Invasive Assessment Methods and Liver Biopsy. PLoS One. 2015;10:e0138838.
[PubMed Abstract] -
15. Lin ZH, Xin YN, Dong QJ, et al. Performance of the aspartate aminotransferase-to-platelet ratio index for the staging of hepatitis C-related fibrosis: an updated meta-analysis. Hepatology. 2011;53:726-36.
[PubMed Abstract] -
16. Suan MAM, Chan HK, Sem X, Shilton S, Hassan MRA. Diagnostic performance of two non-invasive biomarkers used individually and in sequential combination for cirrhosis associated with hepatitis C virus infection. Sci Rep. 2022;12:20153.
[PubMed Abstract] -
17. Holmberg SD, Lu M, Rupp LB, et al. Noninvasive serum fibrosis markers for screening and staging chronic hepatitis C virus patients in a large US cohort. Clin Infect Dis. 2013;57:240-6.
[PubMed Abstract] -
18. Sterling RK, Lissen E, Clumeck N, et al. Development of a simple noninvasive index to predict significant fibrosis in patients with HIV/HCV coinfection. Hepatology. 2006;43:1317-25.
[PubMed Abstract] -
19. Sterling RK, Lissen E, Clumeck N, et al. Development of a simple noninvasive index to predict significant fibrosis in patients with HIV/HCV coinfection. Hepatology. 2006;43:1317-25.
[PubMed Abstract] -
20. Vallet-Pichard A, Mallet V, Nalpas B, et al. FIB-4: an inexpensive and accurate marker of fibrosis in HCV infection. comparison with liver biopsy and fibrotest. Hepatology. 2007;46:32-6.
[PubMed Abstract] -
21. AASLD-IDSA. HCV Guidance: Recommendations for testing, management, and treating hepatitis C. Simplified HCV Treatment for Treatment-Naive Adults With Compensated Cirrhosis.
[AASLD-IDSA Hepatitis C Guidance] -
22. AASLD-IDSA. HCV Guidance: Recommendations for testing, management, and treating hepatitis C. Simplified HCV Treatment for Treatment-Naive Adults Without Cirrhosis.
[AASLD-IDSA Hepatitis C Guidance] -
23. Bhattacharya D, Aronsohn A, Price J, Lo Re V. Hepatitis C Guidance 2023 Update: AASLD-IDSA Recommendations for Testing, Managing, and Treating Hepatitis C Virus Infection. Clin Infect Dis. 2023 May 25;ciad319.
[PubMed Abstract] -
24. Poynard T, Morra R, Halfon P, et al. Meta-analyses of FibroTest diagnostic value in chronic liver disease. BMC Gastroenterol. 2007;7:40.
[PubMed Abstract] -
25. Poynard T, Imbert-Bismut F, Munteanu M, et al. Overview of the diagnostic value of biochemical markers of liver fibrosis (FibroTest, HCV FibroSure) and necrosis (ActiTest) in patients with chronic hepatitis C. Comp Hepatol. 2004;3:8.
[PubMed Abstract] -
26. Koda M, Matunaga Y, Kawakami M, Kishimoto Y, Suou T, Murawaki Y. FibroIndex, a practical index for predicting significant fibrosis in patients with chronic hepatitis C. Hepatology. 2007;45:297-306.

[\[PubMed Abstract\]](#) -

27. Forns X, Ampurdanès S, Llovet JM, et al. Identification of chronic hepatitis C patients without hepatic fibrosis by a simple predictive model. *Hepatology*. 2002;36(4 Pt 1):986-92.
[\[PubMed Abstract\]](#) -
28. Thabut D, Simon M, Myers RP, et al. Noninvasive prediction of fibrosis in patients with chronic hepatitis C. *Hepatology*. 2003;37:1220-1.
[\[PubMed Abstract\]](#) -
29. Haseltine EL, Penney MS, George S, Kieffer TL. Successful treatment with telaprevir-based regimens for chronic hepatitis C results in significant improvements to serum markers of liver fibrosis. *J Viral Hepat*. 2015;22:701-7.
[\[PubMed Abstract\]](#) -
30. Tural C, Tor J, Sanvisens A, et al. Accuracy of simple biochemical tests in identifying liver fibrosis in patients co-infected with human immunodeficiency virus and hepatitis C virus. *Clin Gastroenterol Hepatol*. 2009;7:339-45.
[\[PubMed Abstract\]](#) -
31. Becker L, Salameh W, Sferruzza A, et al. Validation of hepascore, compared with simple indices of fibrosis, in patients with chronic hepatitis C virus infection in United States. *Clin Gastroenterol Hepatol*. 2009;7:696-701.
[\[PubMed Abstract\]](#) -
32. Neuman MG, Cohen LB, Nanau RM. Hyaluronic acid as a non-invasive biomarker of liver fibrosis. *Clin Biochem*. 2016;49:302-15.
[\[PubMed Abstract\]](#) -
33. Patel K, Gordon SC, Jacobson I, et al. Evaluation of a panel of non-invasive serum markers to differentiate mild from moderate-to-advanced liver fibrosis in chronic hepatitis C patients. *J Hepatol*. 2004;41:935-42.
[\[PubMed Abstract\]](#) -
34. Zaman A, Rosen HR, Ingram K, Corless CL, Oh E, Smith K. Assessment of FIBROSpect II to detect hepatic fibrosis in chronic hepatitis C patients. *Am J Med*. 2007;120:280.e9-14.
[\[PubMed Abstract\]](#) -
35. Afdhal NH. Fibroscan (transient elastography) for the measurement of liver fibrosis. *Gastroenterol Hepatol (N Y)*. 2012;8:605-7.
[\[PubMed Abstract\]](#) -
36. Castera L. Noninvasive methods to assess liver disease in patients with hepatitis B or C. *Gastroenterology*. 2012;142:1293-1302.e4.
[\[PubMed Abstract\]](#) -
37. Castera L, Vergniol J, Foucher J, et al. Prospective comparison of transient elastography, Fibrotest, APRI, and liver biopsy for the assessment of fibrosis in chronic hepatitis C. *Gastroenterology*. 2005;128:343-50.
[\[PubMed Abstract\]](#) -
38. Castera L, Forns X, Alberti A. Non-invasive evaluation of liver fibrosis using transient elastography. *J Hepatol*. 2008;48:835-47.
[\[PubMed Abstract\]](#) -

39. Ammon FJ, Kohlhaas A, Elshaarawy O, et al. Liver stiffness reversibly increases during pregnancy and independently predicts preeclampsia. *World J Gastroenterol*. 2018;24:4393-402.
[[PubMed Abstract](#)] -
40. Ziol M, Handra-Luca A, Kettaneh A, et al. Noninvasive assessment of liver fibrosis by measurement of stiffness in patients with chronic hepatitis C. *Hepatology*. 2005;41:48-54.
[[PubMed Abstract](#)] -
41. Steadman R, Myers RP, Leggett L, et al. A health technology assessment of transient elastography in adult liver disease. *Can J Gastroenterol*. 2013;27:149-58.
[[PubMed Abstract](#)] -
42. Kirk GD, Astemborski J, Mehta SH, et al. Assessment of liver fibrosis by transient elastography in persons with hepatitis C virus infection or HIV-hepatitis C virus coinfection. *Clin Infect Dis*. 2009;48:963-72.
[[PubMed Abstract](#)] -
43. Kim HJ, Lee HK, Cho JH, Yang HJ. Quantitative comparison of transient elastography (TE), shear wave elastography (SWE) and liver biopsy results of patients with chronic liver disease. *J Phys Ther Sci*. 2015;27:2465-8.
[[PubMed Abstract](#)] -
44. Verlinden W, Bourgeois S, Gigase P, et al. Liver Fibrosis Evaluation Using Real-time Shear Wave Elastography in Hepatitis C-Monoinfected and Human Immunodeficiency Virus/Hepatitis C-Coinfected Patients. *J Ultrasound Med*. 2016;35:1299-308.
[[PubMed Abstract](#)] -
45. Goyal N, Jain N, Rachapalli V, Cochlin DL, Robinson M. Non-invasive evaluation of liver cirrhosis using ultrasound. *Clin Radiol*. 2009;64:1056-66.
[[PubMed Abstract](#)] -
46. Bonekamp S, Kamel I, Solga S, Clark J. Can imaging modalities diagnose and stage hepatic fibrosis and cirrhosis accurately? *J Hepatol*. 2009;50:17-35.
[[PubMed Abstract](#)] -
47. Kelly EMM, Feldstein VA, Parks M, Hudock R, Etheridge D, Peters MG. An Assessment of the Clinical Accuracy of Ultrasound in Diagnosing Cirrhosis in the Absence of Portal Hypertension. *Gastroenterol Hepatol (N Y)*. 2018;14:367-73.
[[PubMed Abstract](#)] -
48. Wang QB, Zhu H, Liu HL, Zhang B. Performance of magnetic resonance elastography and diffusion-weighted imaging for the staging of hepatic fibrosis: A meta-analysis. *Hepatology*. 2012;56:239-47.
[[PubMed Abstract](#)] -
49. Talwalkar JA, Yin M, Fidler JL, Sanderson SO, Kamath PS, Ehman RL. Magnetic resonance imaging of hepatic fibrosis: emerging clinical applications. *Hepatology*. 2008;47:332-42.
[[PubMed Abstract](#)] -
50. Wang Y, Ganger DR, Levitsky J, et al. Assessment of chronic hepatitis and fibrosis: comparison of MR elastography and diffusion-weighted imaging. *AJR Am J Roentgenol*. 2011;196:553-61.
[[PubMed Abstract](#)] -
51. Li S, Sun X, Chen M, et al. Liver Fibrosis Conventional and Molecular Imaging Diagnosis Update. *J Liver*.

2019;8:236.

[\[PubMed Abstract\]](#) -

52. Ginès P, Krag A, Abraldes JG, Solà E, Fabrellas N, Kamath PS. Liver cirrhosis. *Lancet*. 2021;398:1359-76.
[\[PubMed Abstract\]](#) -
53. Theise ND. Liver biopsy assessment in chronic viral hepatitis: a personal, practical approach. *Mod Pathol*. 2007;20 Suppl 1:S3-14.
[\[PubMed Abstract\]](#) -
54. Bedossa P, Dargère D, Paradis V. Sampling variability of liver fibrosis in chronic hepatitis C. *Hepatology*. 2003;38:1449-57.
[\[PubMed Abstract\]](#) -
55. Gara N, Zhao X, Kleiner DE, Liang TJ, Hoofnagle JH, Ghany MG. Discordance among transient elastography, aspartate aminotransferase to platelet ratio index, and histologic assessments of liver fibrosis in patients with chronic hepatitis C. *Clin Gastroenterol Hepatol*. 2013;11:303-8.
[\[PubMed Abstract\]](#) -
56. Manning DS, Afdhal NH. Diagnosis and quantitation of fibrosis. *Gastroenterology*. 2008;134:1670-81.
[\[PubMed Abstract\]](#) -
57. Regev A, Berho M, Jeffers LJ, et al. Sampling error and intraobserver variation in liver biopsy in patients with chronic HCV infection. *Am J Gastroenterol*. 2002;97:2614-8.
[\[PubMed Abstract\]](#) -
58. Schmeltzer PA, Talwalkar JA. Noninvasive tools to assess hepatic fibrosis: ready for prime time? *Gastroenterol Clin North Am*. 2011;40:507-21.
[\[PubMed Abstract\]](#) -
59. Guido M, Mangia A, Faa G; Gruppo Italiano Patologi Apparato Digerente (GIPAD); Società Italiana di Anatomia Patologica e Citopatologia Diagnostica/International Academy of Pathology, Italian division (SIAPEC/IAP). Chronic viral hepatitis: the histology report. *Dig Liver Dis*. 2011;43 Suppl 4:S331-43.
[\[PubMed Abstract\]](#) -
60. Piccinino F, Sagnelli E, Pasquale G, Giusti G. Complications following percutaneous liver biopsy. A multicentre retrospective study on 68,276 biopsies. *J Hepatol*. 1986;2:165-73.
[\[PubMed Abstract\]](#) -
61. Lefkowitz JH. *Arch Med Res*. Liver biopsy assessment in chronic hepatitis. 2007;38:634-43.
[\[PubMed Abstract\]](#) -
62. Chowdhury AB, Mehta KJ. Liver biopsy for assessment of chronic liver diseases: a synopsis. *Clin Exp Med*. 2023;23:273-85.
[\[PubMed Abstract\]](#) -
63. Knodell RG, Ishak KG, Black WC, et al. Formulation and application of a numerical scoring system for assessing histological activity in asymptomatic chronic active hepatitis. *Hepatology*. 1981;1:431-5.
[\[PubMed Abstract\]](#) -
64. Ishak K, Baptista A, Bianchi L, et al. Histological grading and staging of chronic hepatitis. *J Hepatol*. 1995;22:696-9.
[\[PubMed Abstract\]](#) -

65. Batts KP, Ludwig J. Chronic hepatitis. An update on terminology and reporting. Am J Surg Pathol. 1995;19:1409-17.
[PubMed Abstract] -
66. Malik AH, Kumar KS, Malet PF, Jain R, Prasad P, Ostapowicz G. Correlation of percutaneous liver biopsy fragmentation with the degree of fibrosis. Aliment Pharmacol Ther. 2004;19:545-9.
[PubMed Abstract] -

References

- Boursier J, Bacq Y, Halfon P, et al. Improved diagnostic accuracy of blood tests for severe fibrosis and cirrhosis in chronic hepatitis C. Eur J Gastroenterol Hepatol. 2009;21:28-38.
[PubMed Abstract] -
- Halfon P, Bacq Y, De Muret A, et al. Comparison of test performance profile for blood tests of liver fibrosis in chronic hepatitis C. J Hepatol. 2007;46:395-402.
[PubMed Abstract] -
- Harris R, Harman DJ, Card TR, Aithal GP, Guha IN. Prevalence of clinically significant liver disease within the general population, as defined by non-invasive markers of liver fibrosis: a systematic review. Lancet Gastroenterol Hepatol. 2017;2:288-297.
[PubMed Abstract] -
- Naganuma H, Ishida H, Uno A, Nagai H, Kuroda H, Ogawa M. Diagnostic problems in two-dimensional shear wave elastography of the liver. World J Radiol. 2020;12:76-86.
[PubMed Abstract] -
- Nguyen D, Talwalkar JA. Noninvasive assessment of liver fibrosis. Hepatology. 2011;53:2107-10.
[PubMed Abstract] -
- Patel K, Benhamou Y, Yoshida EM, et al. An independent and prospective comparison of two commercial fibrosis marker panels (HCV FibroSURE and FIBROSpect II) during albinterferon alfa-2b combination therapy for chronic hepatitis C. J Viral Hepat. 2009;16:178-86.
[PubMed Abstract] -
- Rossi E, Adams L, Prins A, et al. Validation of the FibroTest biochemical markers score in assessing liver fibrosis in hepatitis C patients. Clin Chem. 2003;49:450-4.
[PubMed Abstract] -
- Shire NJ, Yin M, Chen J, et al. Test-retest repeatability of MR elastography for noninvasive liver fibrosis assessment in hepatitis C. J Magn Reson Imaging. 2011;34:947-55.
[PubMed Abstract] -
- Talwalkar JA. Elastography for detecting hepatic fibrosis: options and considerations. Gastroenterology. 2008;135:299-302.
[PubMed Abstract] -
- Zarski JP, Sturm N, Guechot J, et al. Comparison of nine blood tests and transient elastography for liver fibrosis in chronic hepatitis C: the ANRS HCEP-23 study. J Hepatol. 2012;56:55-62.
[PubMed Abstract] -

Figures

Figure 1 Aspartate Aminotransferase-to-Platelet-Ratio Index (APRI)

Abbreviations: AST = aspartate aminotransferase

The AST upper limit of normal should be the upper limit of normal established by the laboratory that performed the test. Most laboratories use an AST upper limit of 40 IU/mL.

$$\text{APRI} = \frac{\frac{\text{AST Level}}{\text{AST (Upper Limit of Normal)}}}{\text{Platelet Count (10}^9\text{/L)}} \times 100$$

Figure 2 FIB-4

Abbreviations: AST = aspartate aminotransferase; ALT = alanine aminotransferase

Source: Vallet-Pichard A, Mallet V, Nalpas B, et al. FIB-4: an inexpensive and accurate marker of fibrosis in HCV infection. comparison with liver biopsy and fibrotest. Hepatology. 2007;46:32-6.

$$\text{FIB-4} = \frac{\text{Age (years)} \times \text{AST (U/L)}}{\text{Platelet Count (10}^9\text{/L)} \times \sqrt{\text{ALT (U/L)}}}$$

Figure 3 FibroIndex

Abbreviations: AST = aspartate aminotransferase

Source: Koda M, Matunaga Y, Kawakami M, Kishimoto Y, Suou T, Murawaki Y. FibroIndex, a practical index for predicting significant fibrosis in patients with chronic hepatitis C. *Hepatology*. 2007;45:297-306.

$$\text{FibroIndex} = 1.738 - 0.064 \times \text{platelet count (10}^4\text{/mm}^3\text{)} + 0.005 \times \text{AST (IU/L)} + 0.463 \times \text{gamma globulin (g/dL)}$$

Figure 4 Forns Index

Forns X, Ampurdanès S, Llovet JM, et al. Identification of chronic hepatitis C patients without hepatic fibrosis by a simple predictive model. Hepatology. 2002;36(4 Pt 1):986-92.

Forns Index =

$$\begin{aligned} &7.811 - 3.131 \times \ln(\text{platelet count } [10^9/\text{L}]) \\ &+ \\ &0.781 \times \ln(\text{GGT } [\text{IU/L}]) \\ &+ \\ &3.467 \times \ln(\text{age}) - 0.014 \times \text{cholesterol (mg/dL)} \end{aligned}$$

ln = natural logarithm

GGT = gamma glutamyl transpeptidase

Figure 5 HepaScore (FibroScore)

Becker L, Salameh W, Sferruzza A, et al. Validation of hepascore, compared with simple indices of fibrosis, in patients with chronic hepatitis C virus infection in United States. Clin Gastroenterol Hepatol. 2009;7:696-701.

$$\text{HepaScore} = \frac{y}{y + 1}$$

$$y = \exp[-4.185818 - (0.0249 \times \text{age}) + (0.7464 \times \text{sex}) \\ + (1.0039 \times \alpha 2\text{-macroglobulin}) + (0.0302 \times \text{hyaluronic acid}) \\ + (0.0691 \times \text{bilirubin}) - (0.0012 \times \text{GGT})]$$

Units

age = years

sex (male = 1 and female = 0)

$\alpha 2$ -macroglobulin (g/L)

hyaluronic acid ($\mu\text{g/L}$)

bilirubin ($\mu\text{mol/L}$)

GGT = gamma glutamyl transpeptidase (U/L)

Figure 6 (Image Series) - Castera Transient Elastography Cutoffs (Image Series) - Figure 6 (Image Series) - Castera Transient Elastography Cutoffs
Image 6A: Correlation of Cutoffs and Metavir Fibrosis Scores

Source: Castera L, Vergniol J, Foucher J, et al. Prospective comparison of transient elastography, Fibrotest, APRI, and liver biopsy for the assessment of fibrosis in chronic hepatitis C. Gastroenterology. 2005;128:343-50.

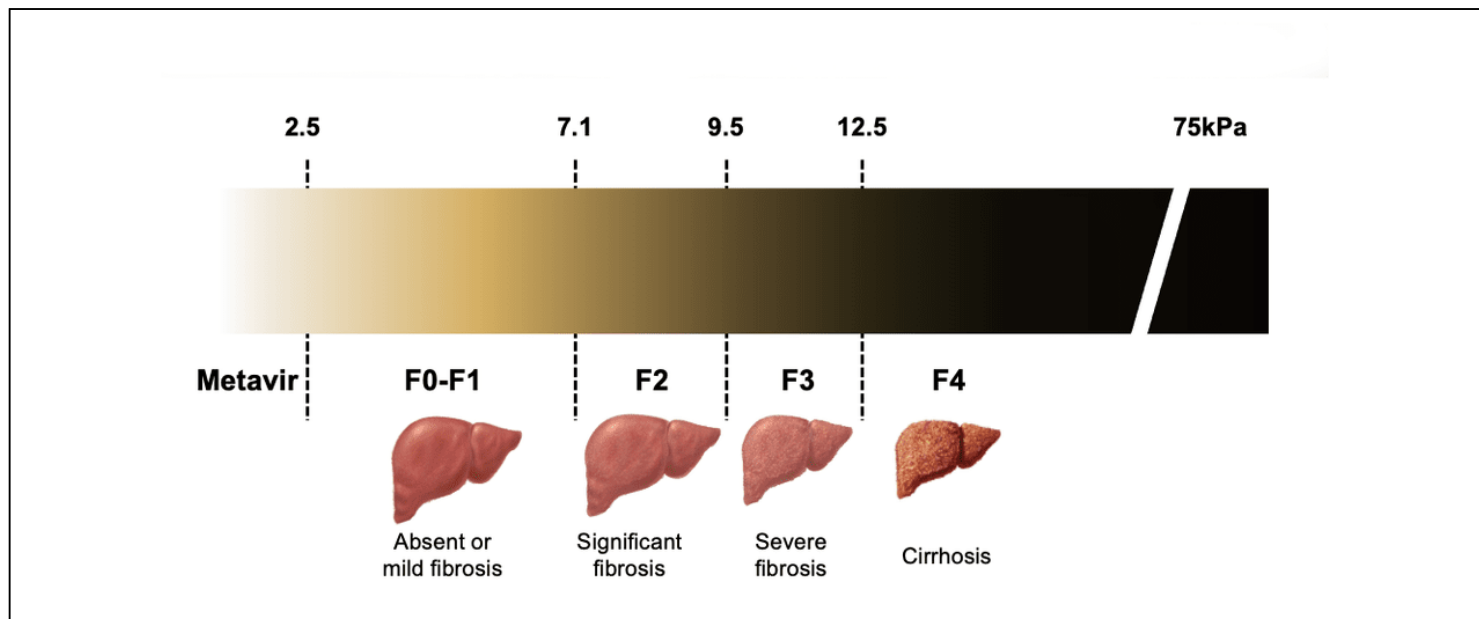


Figure 6 (Image Series) - Castera Transient Elastography Cutoffs
Image 6B: Diagnostic Performance in Persons with HCV Using Castera Cutoffs

Source: Castera L, Forns X, Alberti A. Non-invasive evaluation of liver fibrosis using transient elastography. J Hepatol. 2008;48:835-47.

Diagnostic Performance of Transient Elastography in Persons with HCV Using Castera Cutoffs					
METAVIR Score	Optimal Cutoff*	Sensitivity (%)	Specificity (%)	PPV (%)	NPV (%)
Fibrosis ≥ 2 (F0-1 vs. F2-3-4)	7.1 kPa	67	89	95	48
Fibrosis ≥ 3 (F0-1-2 vs. F3-4)	9.5 kPa	73	91	87	81
Cirrhosis F = 4 (F0-1-2-3 vs. F4)	12.5 kPa	87	91	77	95
*Optimal Cutoff = value that provided higher total sensitivity and specificity Abbreviations: PPV = Positive Predictive Value; NPV = Negative Predictive Value					

Figure 7 (Image Series) - Classification of Liver Histology (Image Series) - Figure 7 (Image Series) - Classification of Liver Histology
Image 7A: Scoring Systems for Histologic Grade (Inflammation)

Abbreviation: IASL = International Association for Study of the Liver

Modified from: Ghany MG, Strader DB, Thomas DL, Seeff LB; American Association for the Study of Liver Diseases. Diagnosis, management, and treatment of hepatitis C: an update. Hepatology. 2009;49:1335-74.

Comparative Scoring Systems for Histologic Grade (Inflammation)		
IASL	Batts-Ludwig	Metavir
Minimal chronic hepatitis	Grade 1	A1
Mild chronic hepatitis	Grade 2	A1
Moderate chronic hepatitis	Grade 3	A2
Severe chronic hepatitis	Grade 4	A3

Figure 7 (Image Series) - Classification of Liver Histology
Image 7B: Scoring Systems for Histologic Stage (Fibrosis)

Abbreviation: International Association for Study of the Liver (IASL)

Modified from: Ghany MG, Strader DB, Thomas DL, Seeff LB; American Association for the Study of Liver Diseases. Diagnosis, management, and treatment of hepatitis C: an update. Hepatology. 2009;49:1335-74.

Comparative Scoring Systems for Histologic Stage (Fibrosis)			
Score	IASL	Batts-Ludwig	Metavir
0	No Fibrosis	No Fibrosis	No Fibrosis
1	Mild fibrosis	Fibrous portal expansion	Periportal fibrotic expansion
2	Moderate fibrosis	Rare bridges or septae	Periportal septae (> 1 septum)
3	Severe fibrosis	Numerous bridges or septae	Portal-central septae
4	Cirrhosis	Cirrhosis	Cirrhosis